



ELSEVIER

# Athletic Hip Injuries and Capsular Laxity

Marc J. Philippon, MD, and Mara L. Schenker, BS

Intra-articular hip injuries are becoming increasingly recognized as a significant cause of pain and decreased performance in the athlete. The introduction of arthroscopic techniques for the treatment of athletic hip injuries, including capsular laxity, has allowed many athletes to return to their high levels of performance. The mechanisms of intra-articular athletic hip injuries, however, have not been well defined. As a result, the establishment of optimal post-arthroscopic rehabilitation protocols and return-to-play guidelines has been difficult. However, based on extensive clinical observation, certain hip injury patterns have been documented for sports in which intra-articular hip pathology are common findings. Oper Tech Orthop 15:261-266 © 2005 Elsevier Inc. All rights reserved.

**KEYWORDS** capsular laxity, thermal capsulorrhaphy, capsular plication, athlete, hip arthroscopy

Hip injuries can be a great source of disability in the athlete. Both recreational and professional athletes alike can suffer from pain, mechanical symptoms (catching and painful clicking), and a significant decline in athletic performance. Depending on the sport, the athlete's hip may be subjected to various extraphysiological forces that are capable of causing acute or chronic injury to the hip. These forces may be in the anterior–posterior, medial–lateral, or rotational planes.<sup>1</sup> The following article will describe some of the specific hip injuries frequently seen in athletes of various sports in addition to the current methods of treating these injuries arthroscopically.

Hip arthroscopy is a valuable diagnostic tool for evaluation of intra-articular pathologies. Ligamentum teres tear, chondral injury, capsular laxity, impingement, and labral injury can now be addressed successfully with arthroscopy. With the development of flexible tools, all areas of the hip joint, central and peripheral, can now be addressed (Fig. 1).<sup>2</sup>

## Clinical Diagnosis

Hip injuries in the athlete often are diagnosed as extra-articular muscle strains or soft tissue contusions. However, within the past decade, various intra-articular pathologies have been identified and treated arthroscopically in the athlete (Table 1).<sup>3</sup> To appropriately direct treatment, a full history and clinical and radiological workup is required in all athletes to differentiate the site of pathology.

Pain is the most commonly reported symptom in athletes with hip injuries.<sup>3</sup> It is a nonspecific indicator of pathology and may be present in the groin, lateral hip, and/or buttocks. The athlete also may complain of mechanical symptoms (catching and painful clicking), similar to those present in meniscal injuries of the knee. Again, these symptoms are nonspecific but may be indicative of intra-articular pathology. The athlete also may complain of tightness and reduced range of motion. These symptoms may be explained by muscular guarding by the iliopsoas or quadratus lumborum or by bony restriction, as in cases of femoroacetabular impingement.

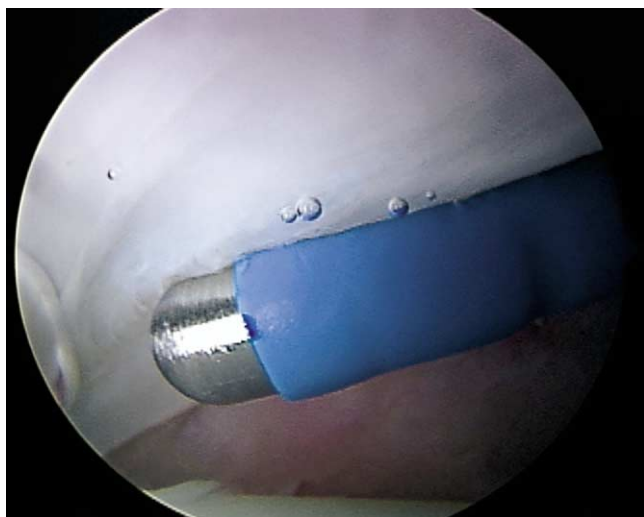
A full clinical workup of an athlete with hip injuries includes examination of both the hip and back.<sup>3</sup> For the hip, it is important to observe gait and posture, active and passive range of motion, pain to palpation of the bursa and surrounding soft tissue, neurovascular health, and response to various provocative maneuvers. Comparison to the uninjured contralateral hip in the clinical examination of the athlete is helpful. The physical examination should also include an examination for capsular laxity and/or generalized ligamentous laxity (hyperextension of the elbows, hypermobility of the shoulders, and increased finger and wrist laxity).<sup>4</sup> Examination for impingement signs are also important.

A full radiological workup of an athlete with hip injuries includes plain radiography, with both anterior-posterior and lateral views. Also, ultrasound, magnetic resonance arthrography, and computerized tomography are helpful tools in visualizing the injured hip.

## Anatomy

The joint capsule and the ligaments provide a thick sleeve surrounding the hip. The iliofemoral ligament dominates the ante-

Steadman Hawkins Research Foundation, Vail, CO.  
Address reprint requests to Marc J. Philippon, MD, Steadman Hawkins Research Foundation, Attn: Clinical Research, 181 W. Meadow Drive, Suite 1000, Vail, CO 81657. E-mail: drphilippon@steadman-hawkins.com



**Figure 1** Flexible arthroscopic tools in the hip joint.

rior capsule. It is approximately 12- to 14-mm thick and is shaped like an inverted “Y.” This ligament provides resistance to hip extension beyond neutral and resists external rotation. The pubofemoral ligament reinforces the inferior and anterior capsule. It resists extension and abduction. The posterior surface of the capsule is reinforced by the ischiofemoral ligament in a spiraling pattern. A deep layer of fibers within the ligamentous capsule provides a constrictive effect in the capsule, thereby helping maintain the femoral head within the acetabulum.

The ligamentum teres is extracapsular and it arises from the margins of the acetabular notch and the transverse acetabular ligament. It attaches to the fovea capitis on the femoral head. Not much has been reported about the function of this ligament, but it is thought that it may participate in joint stability, particularly in secondary stabilization of external rotation in patients with deficient labrums.<sup>5</sup>

The psoas tendon protects the anterior intermediate portion of the joint capsule. The function of this muscle is primarily hip flexion, and due to its anatomical location, it is often subjected to increased load in athletes. This effect is particularly marked in athletes with capsular laxity and joint instability.<sup>3</sup>

## Capsular Laxity

Instability in the hip joint is rarely an issue. Because of the deep recess of the acetabular socket and the strong ligamentous support, the hip joint is inherently stable. However, any deviation from “normal” osseous anatomy places excessive force on the adjacent soft tissues during movement.

Hip instability can be of traumatic or atraumatic origin and often is difficult to diagnose. Traumatic instability is the result of dislocation or subluxation of the femoral head.<sup>6</sup> Most athletic hip dislocations occur in contact sports such as football or hockey. However, at least 2 reported cases of dislocation resulted from the low impact sports of jogging and ballet.<sup>7,8</sup> Hip dislocations can be anterior or central, but posterior dislocations account for 90% of cases.<sup>9,10</sup> Posterior dislocation can result from excessive axial force applied directly to a flexed knee. Hip

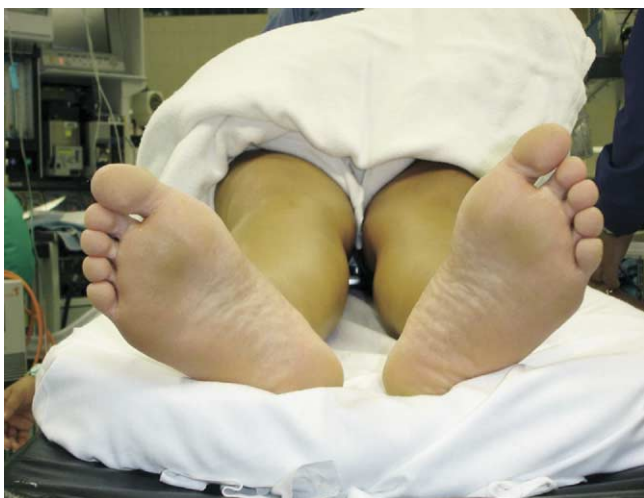dislocations must be treated as orthopaedic emergencies. Hougaard and Thomsen reported that 59% of patients with reduction greater than 6 hours after injury developed avascular necrosis of the femoral head.<sup>11</sup> Additional complications related to hip dislocations include sciatic nerve injury, future degenerative joint disease, hip instability, and chondrolysis.<sup>10,12</sup> Subluxation of the hip without dislocation has been reported in professional football players, resulting from an axial load applied to a flexed and adducted knee.<sup>13,14</sup> In one case, the athlete complained of groin pain but was able to immediately ambulate.<sup>13</sup> He subsequently developed avascular necrosis of the femoral head. Similarly, Lieberman and coworkers reported a case of recurrent hip subluxations and dislocations following a traumatic posterior dislocation in a motor vehicle accident.<sup>15</sup> This patient underwent labral and capsular repair, and the hip became stable.

Atraumatic instability may be a result of overuse, global ligamentous laxity, or disorders such as Ehlers-Danlos syndrome, Down’s syndrome, Marfan syndrome, or developmental dislocation (dysplasia) of the hip (DDH).<sup>16</sup> Bellabarba and coworkers also have described atraumatic hip instability that presented as longstanding painful snapping in the groin with no history of significant trauma.<sup>17</sup> After multiple diagnostic tests, these cases finally were diagnosed with idiopathic hip instability after manual longitudinal traction under fluoroscopy. Most of the patients in this series showed signs of global ligamentous laxity.

In athletes, atraumatic instability is most commonly focal and rotational and associated with elongation of the capsule and labral tear. Abnormal joint stresses may directly injure

**Table 1** Potential Causes of Hip Pain

Intra-articular	Extra-articular
Acetabular labral tears	Hypermobilite iliopsoas tendon
Chondral injuries	Snapping iliotibial tendon
Osteoarthritis	Muscle strain (iliopsoas, gluteus medius, hamstring)
Post-traumatic arthritis	Bursitis (greater trochanteric, iliopsoas, ischial)
Inflammatory arthritis	Tendonitis (rectus femoris, external rotators)
Femoroacetabular impingement (Cam, pincer)	Avulsion injuries
Ligamentum teres tears	Stress fracture of the lesser trochanter
Instability	Sacroiliac joint strain
Capsular sprain	Myositis ossificans
Capsular tightness	Hip pointer
Capsular tear	Infection
Developmental dysplastic hip	
Femoral neck stress fracture	
Osteonecrosis	
Loose bodies	
Slipped capital femoral epiphysis	
Legg–Calve–Perthes disease	
Transient synovitis	
Infection	



**Figure 2** Decreased external rotation endpoint in patient with capsular laxity.

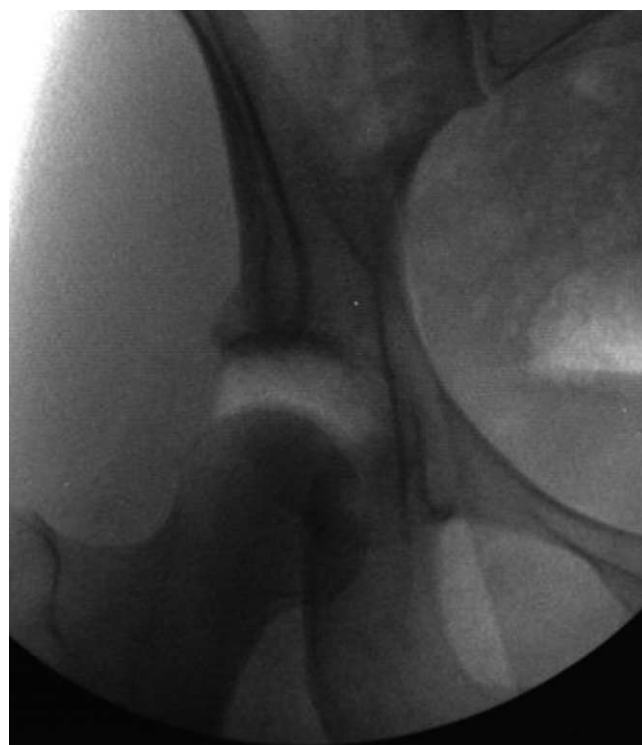the labrum or iliofemoral ligament and can disturb the force balance in the hip.<sup>18,19</sup> Increased tension in the joint capsule and its ligaments may lead to redundancy of the capsule and subsequent instability. In an unpublished study, Martin and coworkers demonstrated that loading a labral-deficient hip can cause significant elongation of the iliofemoral ligament. Instability is a common complaint in professional and high-level athletes participating in sports involving repetitive hip rotation with axial loading (ie, golf, figure skating, football, gymnastics, ballet, baseball, and martial arts).<sup>16</sup>

In athletes with hip instability, the history often provides the most information for diagnosis when the patients can describe the motion that reproduces the symptoms. Patients may complain of feeling their leg “give out” during gait and sport activities.<sup>1</sup> Rotation of the pelvis and external rotation at the hip, such as swinging a golf club or throwing a football across the field, commonly reproduces the sense of instability.<sup>20,21</sup> Other symptoms of hip instability may include pain when rising from a chair, and pain when getting into and out of a car. In physical examination, athletes with instability often present with an audible, painful “pop” when the hip is brought from flexion to extension and/or with axial distraction. In most patients with capsular laxity, there is increased passive range of motion; however, active range of motion is typically equal to that of a normal hip. Hip instability patients also frequently present with a reduced endpoint to hip external rotation. This endpoint can best be observed with the patient in the supine position (Fig. 2). Many patients also have an unusual gait pattern with an abducted and externally rotated gait. In some cases with atraumatic instability, a patient may be able to voluntarily sublux his or her hip. Radiographically, these patients may have a higher Sharp’s angle and a lower center-edge angle. Also, craniolateral inclination of the weight-bearing surface of the acetabulum has been shown to disrupt the force balance in the hip joint, causing a tendency for the femoral head to be pushed out of the acetabulum.<sup>22</sup> In the magnetic resonance arthrogram, a large intra-articular volume and excessive axial distraction may be seen (Fig. 3).

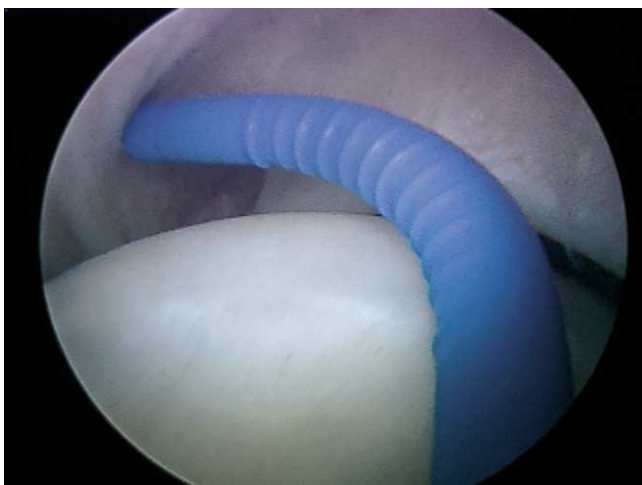
The goal of arthroscopic treatment of hip instability is to re-

duce the volume of the capsule. The procedure may include thermal capsulorrhaphy and/or capsular plication. The use of thermal capsulorrhaphy has faced a great deal of recent controversy. Attenuation of the shoulder capsule has been reported in 20% of patients (71 of 363) who underwent arthroscopic thermal capsulorrhaphy.<sup>23</sup> A prospective self-reported study of arthroscopic shoulder thermal capsulorrhaphy patients demonstrated that 37% (31 of 84) had unsuccessful results.<sup>24</sup> However, several other reports have indicated that with proper patient selection and use of radiofrequency energy, thermal capsulorrhaphy in addition to plication, is a beneficial treatment for joint instability in the shoulder.<sup>25-27</sup> A shoulder cadaveric study showed that suture plication and thermal capsulorrhaphy were effective in reducing glenohumeral intra-articular volume; however, the use of thermal capsulorrhaphy led to greater reduction in capsular volume.<sup>28</sup>

A previously reported supine position is used for hip arthroscopy, and portals are placed anterior, anterolateral, and distal lateral.<sup>29,30</sup> Specialized long, flexible radiofrequency probes have been specifically designed for use in the hip joint (Smith+Nephew, Andover, MA). The thermal capsulorrhaphy procedure used in the hip has been reported previously.<sup>2,16</sup> The area of redundancy is first identified, and the probe is moved across the tissue in a striped pattern (Fig. 4).<sup>31</sup> Tissue response is closely monitored in the color of the tissue (heated tissue appears more yellow and flatter) and in the visual shrinkage of the tissue. It has been shown that adequate tissue must be left between the stripes to allow fibroblasts, which are killed in the treated regions, to repopulate the area.<sup>26</sup> We believe that thermal capsulorrhaphy is a safe and effective treatment for



**Figure 3** Fluoroscopy showing increased capsular volume and excessive axial distraction.



**Figure 4** A flexible monopolar TAC-S radiofrequency energy probe is moved across the capsule in a striped pattern.

hip instability due to the relative thickness of the joint capsule in comparison to the shoulder capsule. However, care must be taken to prevent overheating the tissue by avoiding high probe temperatures and reducing heating time in one capsular region.<sup>2</sup> If thermal capsulorrhaphy cannot safely correct the amount of capsular redundancy, plication may also be performed. A non-absorbable or bioabsorbable No. 2 Vicryl suture is passed through the tissue and tied, creating a tighter capsule (Fig. 5). Sutures may be placed anteriorly and/or posteriorly depending on the quality of the tissue and amount of capsular reduction needed. The plications are performed until excellent capsule tension is observed and there is stability to the capsule on rotational testing. Possible complications from capsular plication include adhesions and capsulitis.

Outcomes after thermal capsulorrhaphy in the hip have been promising. A previous study by the author (M.J.P.) involved a series of high-level athletes, including 2 professional baseball players, 3 professional golfers (PGA), 1 professional football player (NFL), 1 figure skater (Olympic gold medalist), 1 gymnast (Olympic level, bilateral hips), and one ballet dancer; each returned to his or her preinjury level of activity after thermal capsulorrhaphy.<sup>16</sup> They showed an 83% improvement in symptoms using the modified Harris Hip Score. Six years later, these patients are still doing very well, with no evidence of recurrent preoperative symptoms. Plication of the hip capsule has not been studied as thoroughly as thermal capsulorrhaphy. In the shoulder, however, Kelly and coworkers (proceedings of the 50th Annual Meeting of the Orthopaedic Research Society, San Francisco, CA, 2004) looked at the healing response of the capsule after plication in an ovine model. The study found no difference in histologic healing; however, the plication resulted in less tissue trauma when compared with an open capsular shift. Plication of the shoulder capsule has also been shown to decrease capsular volume and affect both the magnitude and direction of glenohumeral translation.<sup>28,32</sup>

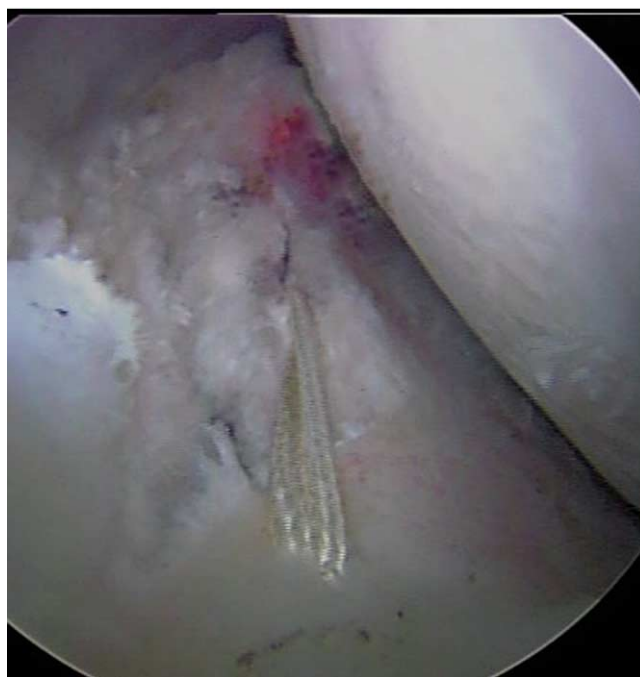## Hip Arthroscopy in Athletes

Injuries requiring hip arthroscopy cover a wide range of sports and hip pathologies (Table 2).<sup>3</sup> Athletes subject their hip joints to extraphysiological forces that can approach 5 times their body weight. Athletic activities, such as running and jumping, twisting, and quickly cutting across the field, can lead to a variety of acute and chronic hip pathologies.

### Golf

Labral tears are a very common finding in a variety of sports, including golfing. In a group of professional golfers, the author (M.J.P.) found that 16 of 16 had labral tears, most of which were anterosuperior; however, 4 golfers also had posterior labral tears.<sup>3</sup> Capsular laxity with associated rotational instability also was found in each of these athletes. Similar to movements in ballet, figure skating, and martial arts, the golf swing forces the hip joint into significant rotation (particularly external) and axial loading. As described previously, this position may cause capsular redundancy, focal instability, and labral tear.

In one study, 10 PGA professional golfers and 6 low-handicap amateur golfers who were diagnosed with labral tears and capsular redundancy underwent laboratory testing of strength, proprioception, balance, flexibility, and swing-motion analysis with electromyogram.<sup>20</sup> A decreased hip abduction moment was found in injured golfers, when compared with healthy controls. An unpublished study (Lephart, Philippon and coworkers presented at the 2002 World Scientific Congress of Golf, St. Andrews, Scotland, July 26, 2002) further showed that coactivation of the hip abductors and adductors resulted in hip stabilization and a lower displacement force. The results of these studies illustrate the importance of hip musculature in hip stability and overall golf performance. Bharam and coworkers



**Figure 5** Suture placed for plication of the capsule.

**Table 2** Hip Pathology in Professional and Olympic-Level Athletes Undergoing Hip Arthroscopy From 1999 to 2005

Sport (No. of Hips)	Labrum (%)	Laxity (%)	Chondral (%)	FAI (%)
Hockey (33)	100	16	94	81
Football (18)	100	25	88	50
Soccer (4)	100	50	100	50
Tennis (5)	100	25	100	25
Dancers (33)	100	100	70	29
Skateboarding (1)	100	0	100	0
Olympic yachting (1)	100	100	0	0
Equestrian (2)	100	50	0	50
Golf (24)	100	100	100	9
Baseball (10)	100	50	80	20
Basketball (5)	100	60	100	0
Martial arts (5)	100	60	60	40
Figure skating (6)	100	100	33	0
Runners (3)	100	100	50	0
Lacrosse (1)	100	0	100	0
Alpine skiing (2)	100	0	100	100
Olympic gymnasts (3)	100	100	66	0
Weightlifting (1)	100	0	100	0
<b>Total (157)</b>	<b>100</b>	<b>58</b>	<b>77</b>	<b>36</b>

(proceedings of the 70th Annual Meeting of the American Academy of Orthopaedic Surgeons, New Orleans, LA, 2003) outlined the typical triad of hip pathologies found frequently in golfers undergoing hip arthroscopy: anterior-superior labral tear, delamination of the labral-chondral junction, and acetabular chondral defect. After hip arthroscopy, the professional golfers returned to play with an average gain of 6 yards in driving distance. Additional studies are needed in the laboratory to compare preoperative strength, proprioception, balance, flexibility, and swing-motion analysis with postoperative results.

## Football

Football players subject their hips to high-impact traumatic injuries, as well as injuries related to axial loading with rotation and often femoroacetabular impingement. Significant chondral defects are frequent arthroscopic findings, often a result of a direct blow to the greater trochanter.<sup>3</sup> Treatment of focal chondral injuries in the athlete may include microfracture of the acetabulum and/or femoral head. Early outcome results for the treatment of chondral injuries in the athlete have been promising. All but one professional football players have returned to play; the remaining professional football player is currently undergoing postoperative rehabilitation.

## Hockey

Hockey players are subjected to similar high-impact traumatic injuries as football players, in addition to injuries related to significant abduction and external rotation movements. Strains of the iliofemoral ligament, femoroacetabular impingement, myositis ossificans, and labral pathology are common findings.<sup>3</sup>

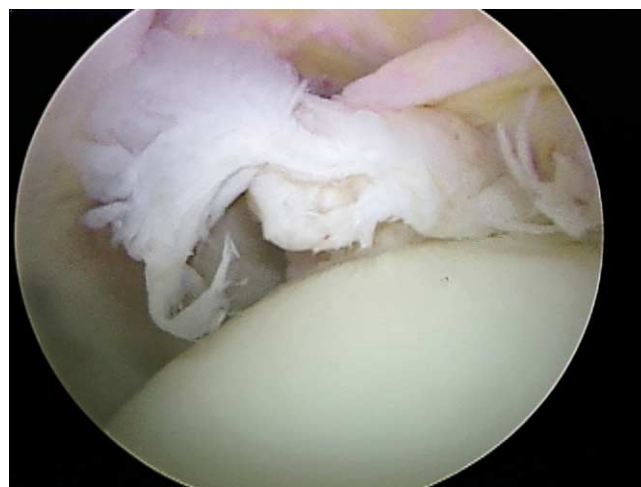
Femoroacetabular impingement (FAI) has been recently revealed as a major cause of athletic hip injury. It is commonly

seen in hockey and football players and it can be the cause of nearly any athletic hip injury. Recently, Ganz and coworkers reported that FAI predisposes a patient to early osteoarthritis.<sup>33-35</sup> Therefore, early diagnosis and treatment of FAI may decrease an athlete's risk of premature osteoarthritis following his or her competitive years. Outcome studies of arthroscopic FAI surgery have been limited. A few studies of the open technique for FAI have shown good results. Beck and coworkers showed that 13 of 19 hips were rated excellent to good (Merle d'Aubigne hip score) in a minimum of 4 year follow-up from open osteoplasty.<sup>36</sup> Murphy and coworkers reported similar results in 23 patients.<sup>37</sup> It is our belief, however, that the arthroscopic approach can provide a shorter rehabilitation time with fewer complications to ensure the athlete a quick return to play. Recently, a review (to be presented at the 73rd Annual Meeting of the American Academy of Orthopaedic Surgeons, Chicago, IL, 2006) of 516 hip arthroscopies completed by one surgeon (M.J.P.) was performed. In this study, 45 (9%) professional athletes from various sports including soccer, football, hockey, baseball, basketball, golf, ballet, martial arts, and horse racing underwent arthroscopic osteoplasty for FAI. All of the hockey players in this study had improvement in symptoms and returned to their sport in 12 to 16 weeks following surgery.

## Ballet

Ballet dancers subject their hips to the extremes of motion, particularly rotation, which can lead to instability secondary to capsular stretching. Associated symptoms may include flexor spasms and quadratus lumborum spasms which may give the false illusion of hip tightness. The athlete may then attempt to further stretch the musculature which can cause additional capsular elongation.<sup>3</sup>

Injuries to the ligamentum teres have been a documented source of intractable hip pain in athletes, including ballet dancers, figure skaters, and martial artists.<sup>3,38</sup> Although tears of the ligament can be the result of traumatic dislocation in any sport, they more commonly have an insidious onset. Repetitive external rotation of the hip and axial loading may cause capsular



**Figure 6** Arthroscopic view of a torn ligamentum teres.

laxity. As a result of the subsequent instability, excess stress may be placed on the ligamentum teres and tears may result (Fig. 6).

Ligamentum teres injuries are most commonly treated with arthroscopic debridement, but they may also be primarily repaired or reconstructed using an iliotibial band graft.<sup>30</sup> Simple debridement of the tear is not thought to be sufficient treatment for athletes involved in sports such as martial arts, in which external rotatory and axial distraction forces are high, because the function of the ligamentum teres is thought to be secondary stabilization of external rotation.<sup>39</sup> Therefore, the ligamentum teres may be a very important structure in sports such as martial arts. Thus, repair or reconstruction should be considered in these patients.

## Discussion

Elite athletes are subjected to extreme forces and ranges of motion in their everyday sport activity. The hip joint is highly affected by the additional stresses, and the athlete is prone to developing hip injuries. Injury mechanisms may be acute and traumatic, or repetitive from overuse. Hip injuries in athletes that do not resolve over the course of a 4-6 week time period should prompt further investigation into possible intra-articular damage.

In the relatively short time period that hip arthroscopy has become an option, many athletes have been relieved of pain, and are promptly returning to their high levels of activity. Good arthroscopic technique, a well-defined rehabilitation protocol, and appropriate patient selection are critical for success of this technique.

## References

1. Tsai Y-S, McCrory JL, Sell TC, et al: Hip strength, flexibility, and standing posture in athletes with an acetabular labral tear. *J Orthop Sports Phys Ther* 34:A55-A56, 2004 (abstr)
2. Schenker ML, Philippon MJ: The role of flexible radiofrequency energy probes in hip arthroscopy. *Tech Ortho* 20:37-44, 2005
3. Philippon MJ: Arthroscopy of the hip in the management of the athlete, in McGinty JB (ed): *Operative Arthroscopy* (ed 3). Philadelphia, Lippincott, Williams & Wilkins, 2003, pp 879-883
4. Philippon MJ: The role of arthroscopic hip labral repair and capsulorrhaphy in the treatment of hip disorders. *Instr Course Lect* (in press)
5. Rao J, Zhou YX, Villar RN: Injury to the ligamentum teres: Mechanism, findings, and results of treatment. *Clin Sports Med* 20:791-799, 2001
6. Scopp JM, Moorman CT: Acute athletic trauma to the hip and pelvis. *Orthop Clin N Am* 33:555-563, 2002
7. Wolfe MW, Brinker MR, Cary GR, et al: Posterior fracture-dislocation of the hip in a jogger. *J South Orthop Assoc* 4:91-95, 1995
8. Stein DA, Polatsch DB, Gidumal R, et al: Low-energy anterior hip dislocation in a dancer. *Am J Ortho* 31:591-594, 2002.
9. Boyd KT, Peirce NS, Batt ME: Common hip injuries in sport. *Sports Med* 24:273-288, 1997
10. Henry JH: Traumatic injuries to the hip. Part I: Fractures and dislocations of the hip, in Baker CL (ed): *The Houston Clinic Sports Medicine Book*. Baltimore, Lippincott, Williams & Wilkins, 1995, pp 392-398
11. Hougaard K, Thomsen PB: Traumatic posterior dislocation of the hip—prognostic factors influencing the incidence of avascular necrosis of the femoral head. *Arch Orthop Trauma Surg* 106:32-35, 1986
12. DeLee JC: Fractures and dislocations of the hip, in Rockwood CA, Green DP, Bucholz RW (eds): *Rockwood and Green's Fractures in Adults* (ed 4). Philadelphia, JB Lippincott Co, 1994, pp. 1659-1825
13. Cooper DE, Warren RF, Barnes R: Traumatic subluxation of the hip resulting in aseptic necrosis and chondrolysis in a professional football player. *Am J Sports Med* 19:322-324, 1991
14. Moorman CT, Warren RF, Hershman EB, et al: Traumatic posterior hip subluxation in American football. *J Bone Joint Surg* 85A:1190-1196, 2003
15. Lieberman JR, Altchek DW, Salvati EA: Recurrent dislocation of a hip with a labral lesions: Treatment with a modified Bankart-type repair: Case report. *J Bone Joint Surg* 75A:1524-1527, 1993
16. Philippon MJ: The role of arthroscopic thermal capsulorrhaphy in the hip. *Clin Sports Med* 20:817-829, 2001
17. Bellabarba C, Sheinkop MB, Kuo KN: Idiopathic hip instability: An unrecognized cause of coax saltans in the adult: *Clin Orthop* 355:261-271, 1988
18. Ferguson SJ, Bryant JT, Ganz R, et al: The acetabular labrum seal: A poroelastic finite element model. *Clin Biomech* 15:463-468, 2000
19. Ferguson SJ, Bryant JT, Ganz R, et al: An in vitro investigation of the acetabular labral seal in hip joint mechanics. *J Biomech* 36:171-178, 2003
20. McCrory JL, Tsai Y-S, Sell TC, et al: Biomechanics of the hip joint in golfers with a history of labral tears (abstr). *Med Sci Sports Exercise* 35:S27, 2003 (suppl)
21. Tsai Y-S, Sell TC, Myers JB, et al: The relationship between hip muscle strength and golf performance (abstr). *Am Col Sports Med* 36:S9, 2004 (suppl)
22. Bombelli R: *Structure and Function in Normal and Abnormal Hips* (ed 3). New York, Springer-Verlag, 1993, pp 24-27
23. Wirth MA, Groh GI, Rockwood CA: Capsulorrhaphy through an anterior approach for the treatment of atraumatic posterior glenohumeral instability with multidirectional laxity of the shoulder. *J Bone Joint Surg Am* 80:1570-1578, 1998
24. D'Alessandro DF, Bradley JP, Fleischli JE, et al: Prospective evaluation of thermal capsulorrhaphy for shoulder instability: Indications and results, two- to five-year follow-up. *Am J Sports Med* 32:21-33, 2004
25. Mazzocca AD, Brown FM, Carreira DS, et al: Arthroscopic anterior shoulder stabilization of collision and contact athletes. *Am J Sports Med* 33:52-60, 2005
26. Anderson K, Warren RF, Altchek DW, et al: Risk factors for early failure after thermal capsulorrhaphy. *Am J Sports Med* 30:103-107, 2002
27. Lephart SM, Myers JB, Bradley JP, et al: Shoulder proprioception and function following thermal capsulorrhaphy. *Arthroscopy* 18:770-778, 2002
28. Karas SG, Creighton RA, DeMorat GJ: Glenohumeral volume reduction in arthroscopic shoulder reconstruction: A cadaveric analysis of suture plication and thermal capsulorrhaphy. *Arthroscopy* 20:179-184, 2004
29. Kelly BT, Williams RJ: Hip Arthroscopy: Current indications, treatment options, and management issues. *Am J Sports Med* 31:1020-1037, 2003
30. Schenker ML, Martin RR, Weiland DE, et al: Current trends in hip arthroscopy: A review of injury diagnosis, techniques, and outcome scoring. *Current Op Ortho* 16:89-94, 2005
31. Lu Y, Hayashi K, Edwards RB: The effect of monopolar radiofrequency treatment pattern on joint capsular healing: In vitro and in vivo studies using an ovine model. *Am J Sports Med* 28:711-719, 2000
32. Werner CML, Nyffeler RW, Jacob HAC, et al: The effect of capsular tightening on humeral head translations. *J Ortho Res* 22:194-201, 2004
33. Beck M, Kalthor M, Leunig M, et al: Hip morphology influences the pattern of damage to the acetabular cartilage: Femoroacetabular impingement as a cause of early osteoarthritis in the hip. *J Bone Joint Surg Br* 87:1012-1018, 2005
34. Ganz R, Parvizi J, Beck M, et al: Femoroacetabular impingement: A cause for osteoarthritis of the hip: *Clin Orthop* 217:112-120, 2003
35. Leunig M, Casillas MM, Hamlet M, et al: Stipped capital femoral epiphysis: Early mechanical damage to the acetabular cartilage by a prominent femoral metaphysis. *Acta Orthop Scand* 71:370-375, 2000
36. Beck M, Leunig M, Parvizi J, et al: Anterior femoroacetabular impingement: Mid-term results of surgical treatment. *Clin Orthop* 418:67-73, 2004
37. Murphy S, Tannast M, Kim YJ, et al: Debridement of the adult hip for femoroacetabular impingement: Indications and preliminary clinical results. *Clin Orthop* 429:178-181, 2004
38. Byrd JW, Jones KS: Traumatic rupture of the ligamentum teres as a source of hip pain. *Arthroscopy* 20:385-391, 2004
39. Gray AJR, Villar RN: The ligamentum teres of the hip: An arthroscopic classification of its pathology. *Arthroscopy* 13:575-578, 1997