

---

## Substance P and mast cells: Preliminary histologic analysis of the human temporomandibular joint

Charles H. Henry, DDS,<sup>a</sup> and Larry M. Wolford, DDS,<sup>b</sup> Keene, NH, and Dallas, Tex  
BAYLOR COLLEGE OF DENTISTRY

**Purpose.** Neuropeptide-containing nerves can serve as a mechanism for nervous system regulation of host defense responses. Because bacteria associated with reactive arthritis have been identified in the temporomandibular joint (TMJ), this study investigates whether the presence of substance P (SP) neuropeptide-containing nerves and mast cells can be identified in the TMJ.

**Material and methods.** Posterior bilaminar tissue removed during TMJ surgery from 9 women was evaluated for the presence of neuropeptide-containing nerves by staining with a monoclonal antibody to SP. Staining of the TMJ tissue sections with 0.5% toluidine blue was performed to identify the presence of mast cells.

**Results.** SP-containing nerves and mast cells were identified within the posterior bilaminar tissue associated with the vasculature.

**Conclusions.** The presence of neuropeptide nerves and mast cells within the TMJ has been shown. Mast cell degranulation products and SP release can contribute to TMJ inflammation.

(*Oral Surg Oral Med Oral Pathol Oral Radiol Endod* 2001;92:384-9)

Neuropeptides can be released from activated peripheral nerve terminals into the surrounding tissue and evoke an inflammatory response. *Neurogenic inflammation* is the term used to describe this phenomenon. Substance P (SP) and calcitonin gene-related peptide (CGRP) are examples of neuropeptides that can induce an inflammatory response by the activation of proinflammatory cytokines and arachidonic acid catabolism when injected into tissue.<sup>1-3</sup> These neuropeptides are usually associated with the central and peripheral terminals of C-fiber neurons. Axonal transport to peripheral terminals has been shown to be increased in neurons supplying inflamed tissues.<sup>4</sup> Nerve terminals containing SP and CGRP have been demonstrated in the temporomandibular joints (TMJs) of various animals.<sup>5-7</sup> Nerve fibers containing SP and CGRP have been shown to be distributed primarily in the joint capsule, the peripheral articular disk, synovial membrane, and the periosteum of rat TMJ.<sup>5</sup>

In the human TMJ, evaluation of the presence of neuropeptides in the synovial fluid of the TMJ has been performed.<sup>8-10</sup> Neuropeptide-containing nerves have been demonstrated by immunostaining within the human TMJ capsule.<sup>11</sup> Measurable concentrations of SP within the posterior bilaminar tissue have been evaluated in patients with degenerative TMJ disease.<sup>12</sup> No

significant differences in SP concentrations between patients were identified.

A spatial association between mast cells and peptidergic nerves containing neuropeptides has been demonstrated in the gastrointestinal tract, suggesting a functional relationship.<sup>13</sup> Neuropeptides are known to affect an array of immune functions such as natural killer cell activity and Ig synthesis.<sup>14</sup> SP also appears to enhance the endocytotic ability of macrophages and neutrophils.<sup>15</sup>

Mast cells and SP-containing nerves are prominent perivascularly in the superficial rat synovium.<sup>16</sup> A parallel distribution of mast cells and neuropeptide-containing nerves was demonstrated in all sections of the normal synovium. In the human TMJ, the subintimal tissue of the synovial membrane contains fibroblasts, macrophages, and mast cells, in addition to blood vessels and lymphatics.<sup>17</sup> Degranulation of mast cells can be stimulated by microorganisms and the neuropeptides neurotensin, somatostatin, vasoactive intestinal peptide, and SP.<sup>18,19</sup> However, only SP evokes histamine release from mast cells. Mast cells can also release serotonin (5-HT) on degranulation. Serotonin can also be released from mast cells in response to interactions with neuropeptide Y. Serotonin can produce hyperalgesia by direct action on the 5-HT<sub>1A</sub> receptors of the primary afferent sensory neurons.<sup>20</sup> Mast cells are also a primary cellular source of neurotrophins (ie, nerve growth factor).<sup>21</sup> Nerve growth factor has been shown to induce pressure allodynia, as well as lowered heat-pain threshold, in humans.<sup>22</sup>

This study investigates whether the presence of neuropeptide-containing nerves, as well as mast cells, can be identified within the posterior bilaminar tissue of the human TMJ in patients with internal derangement.

<sup>a</sup>In private practice, Keene, NH.

<sup>b</sup>Clinical Professor of Oral and Maxillofacial Surgery, Baylor College of Dentistry—Texas A & M University System. In private practice, Baylor University Medical Center, Dallas, Tex.

Received for publication Aug 7, 2000; returned for revision Nov 18, 2000; accepted for publication Jun 7, 2001.

Copyright © 2001 by Mosby, Inc.

1079-2104/2001/\$35.00 + 0 7/12/117811

doi:10.1067/moe.2001.117811

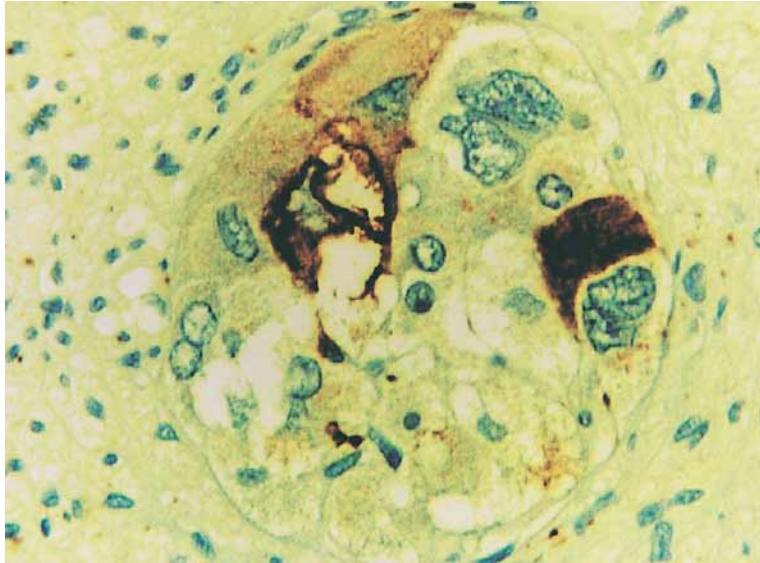


Fig 1. Positive control staining of neuroendocrine carcinoma sections for SP was appropriate (brown material; original magnification  $\times 600$ ).

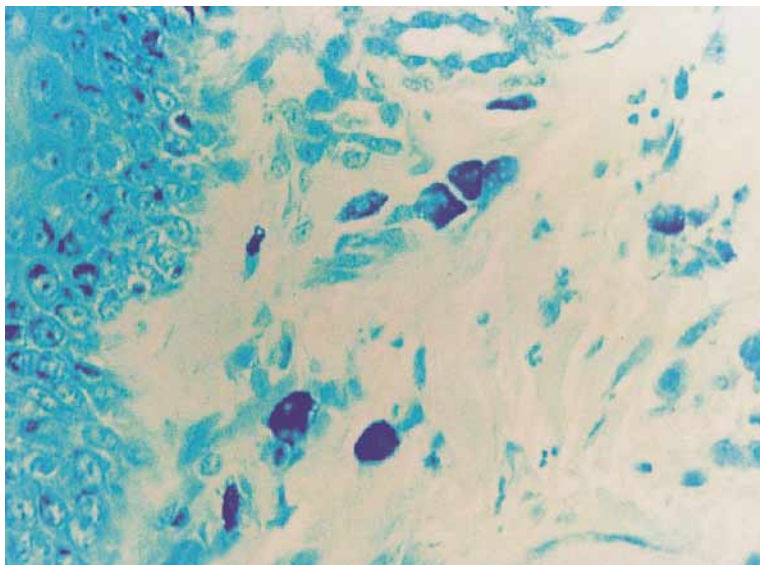


Fig 2. Positive control staining of mastocytoma sections for mast cells was appropriate (original magnification  $\times 600$ ).

## PATIENTS AND METHODS

Posterior bilaminar tissue of the TMJ, which is usually removed and discarded during surgery for articular disk repositioning and posterior ligament repair, was obtained from 9 female patients. Tissue samples were immediately snap-frozen in liquid nitrogen, embedded in OCT medium (Sakura Finetek, Torrance Calif), and stored at  $-70^{\circ}\text{C}$  until processing. Our project followed the guidelines of the Institutional Review Board of Baylor Medical Center and received approval. For all patients, this was the first surgical

intervention to correct internal derangement of the TMJ. The average age of the patients was 38 years (32-46 years). Four patients (44%) had unilateral TMJ dysfunction, and 5 patients (56%) had bilateral dysfunction. All patients studied were diagnosed with articular disk dislocation and most had varying degrees of degenerative joint disease of the TMJ. Eight patients were previously diagnosed as having the presence of *Chlamydia trachomatis* within the posterior bilaminar tissue by polymerase chain reaction assay.<sup>23</sup>

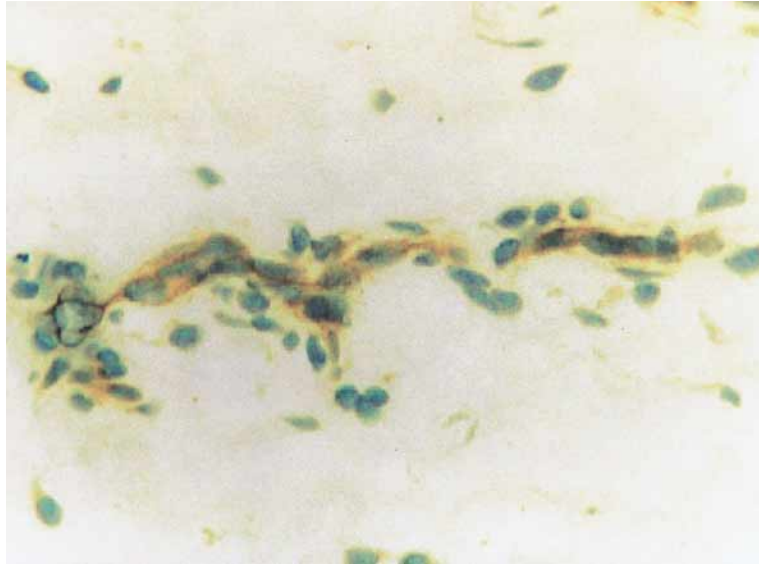

Fig 3. Stained tissue sections from patient TMJ sample indicating presence of SP-containing nerves within walls of vasculature (brown granular material; original magnification  $\times 600$ ).

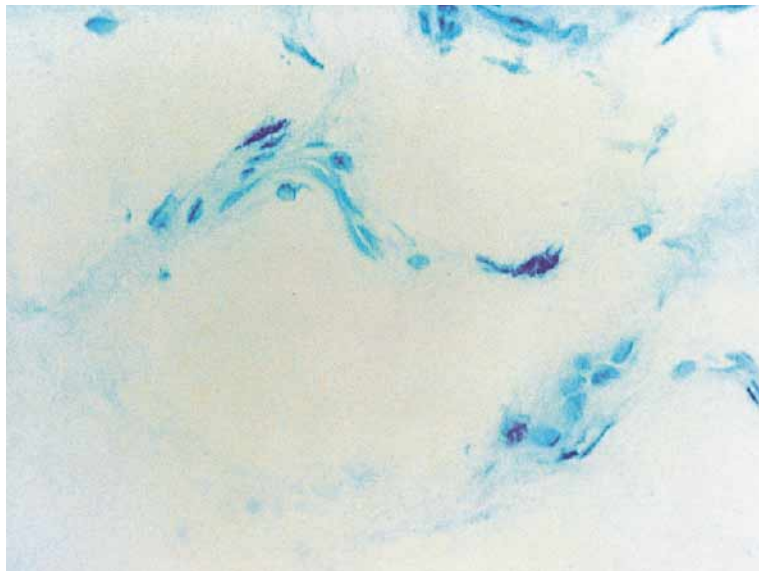


Fig 4. Mast cells within posterior bilaminar tissue of TMJ associated with the vasculature (original magnification  $\times 600$ ).

### Immunohistochemical analyses

Five-millimeter sections were prepared from OCT tissue blocks, then mounted on capillary gap slides (ChemMate; Ventana Medical Systems, Tucson, Ariz). Specimens were then incubated in blocking antibody serum (ChemMate; Ventana Medical Systems) for 5 minutes. A primary monoclonal antibody (Ab) designed for specific and qualitative localization of SP (BioGenex Laboratories, San Ramon, Calif) was used. Before use, Ab was diluted 1:80 with 1% PBS (pH 7.4) and then was incubated with the specimens at 37°C for

30 minutes. Negative controls were incubated without primary Ab. Specimens were rinsed in buffer. Secondary staining with biotinylated polyvalent Ab (rabbit, mouse IgM, mouse IgG) was done by incubation at 37°C for 20 minutes, followed by two PBS rinses, then a 20-minute 37°C incubation with avidin-biotin complex (ChemMate; Ventana Medical Systems). Specimens were rinsed in PBS, incubated in a DAB chromogenic bath (ChemMate; Ventana Medical Systems) for 5 minutes, then counterstained in hematoxylin for 1 minute. Automated processing of

staining procedures was done on a Bio-Tek 1000 (Ventana Medical Systems). Staining of neuroendocrine carcinoma sections was used to provide positive control staining of nerves containing SP (Fig 1). No control nondysfunctional TMJ tissue was available for SP evaluation. To stain for mast cells, TMJ tissue sections were placed into 0.1% toluidine blue (pH 0.5) for 10 minutes, quickly dehydrated, and mounted. Sections from a mastocytoma were used for positive mast cell control staining (Fig 2).

## RESULTS

All tissue specimens were examined for the presence of neuropeptide-containing nerves by immunohistochemical staining. All TMJ specimens examined were positive for the presence of SP-containing nerves (Fig 3). All positive patients were female, and their average age was 38 years (range, 32-46 years). Positive control staining of neuroendocrine carcinoma sections was appropriate (Fig 1). Histologic analysis of the stained tissue sections from positive patient samples indicated a predominance of signal for the SP-containing nerves within the walls of the vasculature (Fig 3). Negative experimental TMJ tissue specimens, processed without primary anti-SP Ab, showed an appropriate lack of positive signal. The presence of mast cells associated with the vasculature was demonstrated (Fig 4).

## DISCUSSION

Our study demonstrates the presence of SP and mast cells associated with the vasculature within the posterior bilaminar tissue of the human TMJ in patients with anterior disk dislocation. The presence of mast cells and peptidergic nerves containing neuropeptides within the TMJ suggests that a functional relationship may exist that is similar to that believed to exist in the gastrointestinal tract.<sup>13</sup> It is postulated that the bidirectional communication between mast cells and nerves may serve as a homeostatic unit in the regulation of gut physiology and host defense to elicit antigen eradication or inactivation.

The presence of SP immunoreactive fibers has been demonstrated in the capsule, disk attachments, and within the adventitia of arteries—but not of veins—of the TMJ of *Macaca fascicularis*.<sup>7</sup> Calcitonin gene-related peptide, neuropeptide Y, and vasoactive intestinal polypeptide-containing nerves show a similar distribution in the rat TMJ.<sup>5,6</sup> Neuropeptides neurokinin A, CGRP, neuropeptide Y, and vasoactive intestinal polypeptide have been demonstrated in the synovial fluid of the TMJ in patients with arthropathy.<sup>8</sup>

Mast cells and SP-containing nerves are prominent perivascularly in the superficial rat synovium, where they may have early contact with any microorganism

arriving via the microvessels.<sup>24</sup> Our previous studies have shown the presence of *C trachomatis* and other bacteria associated with reactive arthritis in the perivascular tissue of the posterior bilaminar tissue in approximately two-thirds of the TMJs evaluated.<sup>23,25-28</sup>

The localization of *C trachomatis* and other bacteria to the TMJ may occur as a consequence of the perivascular location of mast cells that can bind infectious agents. Neuropeptides SP and substance K have been shown to induce the production of interleukin-1 (IL-1), interleukin-6 (IL-6), and tumor necrosis factor (TNF)- $\alpha$  from human monocytes.<sup>1</sup> The concentration of IL-1, IL-6, and TNF has been shown to be higher in the TMJs of patients with internal derangement than in control subjects.<sup>29-31</sup> Local production of TNF within the TMJ has been shown in patients with chronic connective tissue disease.<sup>32</sup>

Mast cell–neuropeptide nerve interaction in the regulation of the mucosal/epithelial response to antigen has been shown in the intestines.<sup>33</sup> Mast cells can release histamine, leukotrienes, and prostaglandins in response to antigen challenge. Previously, Quinn and Bazan<sup>34</sup> detected the presence of prostaglandin E<sub>2</sub> and leukotriene B<sub>4</sub> in the synovial fluid of painful, dysfunctional TMJs. More recently, Alstergren and Kopp<sup>35</sup> have shown an increased level of prostaglandin E<sub>2</sub> in the synovial fluid of patients with inflammatory disorders of the TMJ versus plasma levels, thus indicating the intra-articular production of prostaglandin E<sub>2</sub>.

The subintimal tissue of the TMJ synovial membrane has been shown to contain fibroblasts, macrophages, and mast cells, as well as blood vessels and lymphatics.<sup>17</sup> Mast cells can also synthesize a variety of cytokines that can direct mucosal immune reactions, including transforming growth factor- $\beta$ .<sup>13</sup> It has been postulated that the sustained production of transforming growth factor- $\beta$  may account for the observation of intimal hyperplasia, an increase in the number of fibroblasts in the subintimal tissue, and fibrosis seen in the synovial membrane of osteoarthritic TMJs.<sup>36</sup> Our previous study showed an area of synovial hyperplasia with a collection of *C trachomatis*-infected cells in the subsynovial layer.<sup>23</sup>

Reactive arthritis as a consequence of triggering *C trachomatis* infections has been extensively studied to understand the pathogenetic mechanisms of inflammatory arthritis.<sup>37-41</sup> Although speculative, the presence of mast cells within the synovial and the perivascular tissues of the TMJ and neuropeptide-containing nerves suggests a potent mechanism for nervous system regulation of host defense responses to bacterial infections. The etiology of inflammation within the TMJ may occur in response to the presence of microorganisms within the tissues of the TMJ and may be augmented

by various pathways,<sup>42</sup> including the nervous system, thus resulting in degenerative changes in the collagen of the posterior ligament, internal derangement, and degenerative joint disease.

We thank Vincent A. Memoli, MD, Professor of Pathology, Christine Hodorowski, and Karlya Wheeler for their technical assistance in the Pathology Laboratory, Dartmouth-Hitchcock Medical Center, Lebanon, NH.

## REFERENCES

- Lotz M, Vaughan JH, Carson DA. Effect of neuropeptides on production of inflammatory cytokines by human monocytes. *Science* 1988;241:1218-21.
- Said SI. Neuropeptides as modulators of injury and inflammation. *Life Sci* 1990;47:19-21.
- Pedersen-Bjergaard U, Nielsen LB, Jensen K, Edvinsson L, Jansen I, Olesen J. Calcitonin gene-related peptide, neurokinin A and substance P: Effects on nociception and neurogenic inflammation in human skin and temporal muscle. *Peptides* 1991;12:333-7.
- Donnerer J, Schuligoi R, Stein C. Increased content and transport of substance P and calcitonin gene-related peptide in sensory nerves innervating inflamed tissue: Evidence for a regulatory function of nerve growth factor in vivo. *Neuroscience* 1992;49:693-8.
- Kido MA, Kiyoshima T, Kondo T, Ayasaka N, Moroi R, Terada Y, et al. Distribution of substance P and calcitonin gene-related peptide-like immunoreactive nerve fibers in the rat temporomandibular joint. *J Dent Res* 1993;72:592-8.
- Ichikawa H, Wakisaka S, Matsuo S, Akai M. Peptidergic innervation of the temporomandibular disk in the rat. *Experientia* 1989;303-4.
- Johansson A, Isacson G, Isberg A, Granholm A. Distribution of substance P-like immunoreactive nerve fibers in temporomandibular joint soft tissues of monkey. *Scand J Dent Res* 1986;94:225-32.
- Holmlund A, Ekblom A, Hansson P, Lind J, Lundeberg T, Theodorsson E. Concentrations of neuropeptides substance P, neurokinin A, calcitonin gene-related peptide, neuropeptide Y and vasoactive intestinal polypeptide in synovial fluid of the human temporomandibular joint. A correlation with symptoms, signs and arthroscopic findings. *Int J Oral Maxillofacial Surg* 1991;20:228-31.
- Kopp S. The influence of neuropeptides, serotonin, and Interleukin 1 $\beta$  on temporomandibular joint pain and inflammation. *J Oral Maxillofac Surg* 1998;56:189-91.
- Appelgren A, Appelgren B, Eriksson S, Kopp S, Lundeberg T, Nylander M, et al. Neuropeptides in temporomandibular joints with rheumatoid arthritis: a clinical study. *Scand J Dent Res* 1991;99:519-21.
- Harrison SD, Hukkanen M, Polak JM, Harris M. Immunolocalization of neuropeptides in the TMJ capsule. *J Dent Res (Divisional Abstracts:British Division #344)* 1993;72:729.
- Franco P, Talwar R, Medina D. Substance P levels in hyperplastic retrodiscal tissues of patients with degenerative temporomandibular joint disease. *J Oral Maxillofac Surg (Supplement 1, Poster 26)* 1999;57:116.
- McKay DM, Bienenstock J. The interaction between mast cells and nerves in the gastrointestinal tract. *Immunol Today* 1994;15:533-8.
- McKay DM, Djuric VJ, Perdue MH, Bienenstock J. In: Heatly RV, editor. *Gastrointestinal and hepatic immunology*. Cambridge (UK): Cambridge University Press; 1995. p. 48-75.
- Bar-Shavit Z, Goldman R, Stabinsky Y, Gottlieb P, Fridkin M, Teichberg VI, et al. Enhancement of phagocytosis—a newly found activity of substance P residing in its N-terminal tetrapeptide sequence. *Biochem Biophys Res Commun* 1980;94:1445-51.
- Hukkanen M, Grönblad M, Rees R, Kottinen YT, Gibson SJ, Hietanen J, et al. Regional distribution of mast cells and peptide containing nerves in normal and adjuvant arthritic rat synovium. *J Rheumatol* 1991;18:177-83.
- Dijkgraaf LC, de Bont LG, Boering G, Liem RS. Structure of the normal synovial membrane of the temporomandibular joint: A review of the literature. *J Oral Maxillofac Surg* 1996;54:332-8.
- Carraway RE, Cochrane DE, Granier C, Kitabgi P, Leeman E, Singer EA. Parallel secretion of endogenous 5-hydroxytryptamine and histamine from mast cells stimulated by vasoactive peptides and compound 48/80. *Br J Pharmacol* 1984;81:227-9.
- Bisset GW, Lewis GP. A spectrum of pharmacological activity in some biologically active peptides. *Br J Pharmacol* 1962;19:168-73.
- Taiwo YO, Levine JD. Serotonin is a directly acting hyperalgesic agent in the rat. *Neuroscience* 1992;48:485-90.
- Dines KC, Powell HC. Mast cell interactions with the nervous system: Relationship to mechanisms of disease. *J Neuropathol Exp Neurol* 1997;56:627-40.
- Dyck PJ, Peroutka S, Rask C, Burton E, Baker MK, Lehman KA, et al. Intradermal recombinant human nerve growth factor induces pressure allodynia and lowered heat-pain threshold in humans. *Neurology* 1997;48:501-5.
- Henry CH, Hudson AP, Gérard HC, Franco PF, Wolford LM. Identification of Chlamydia trachomatis in the human temporomandibular joint. *J Oral Maxillofac Surg* 1999;57:683-8.
- Schumacher HR Jr. How micro-organisms are handled to localize to joints and within joints. *Scand J Rheumatol Suppl* 1995;101:199-202.
- Henry CH, Hughes CV, Gérard HC, Hudson AP, Wolford LM. Reactive arthritis: Preliminary microbiologic analysis of the human temporomandibular joint. *J Oral Maxillofac Surg* 2000;58:1137-42.
- Henry CH, Hughes CV, Babae R, Hudson AP, Wolford LM. Bacteria associated with reactive arthritis and the temporomandibular joint. Presented at the AAOMS 81st Annual Meeting Boston, MA, September 29-Oct 2, 1999.
- Henry CH, Hughes CV, Hudson AP, Wolford LM. Identification of bacteria associated with reactive arthritis in the human temporomandibular joint. Presented at the 14th International Conference on Oral and Maxillofacial Surgery, Washington, DC, April 24-29, 1999. *Int J Oral Maxillofac Surg* 1999;28(Suppl 1):19.
- Hughes CV, Henry CH, Majzner RG, Gérard HC, Hudson AP, Wolford LM. *Mycoplasma genitalium* and *Mycoplasma fermentans* in the human temporomandibular joint [abstract]. *J Dent Res (Abstract# 2509)* 1999;78:419.
- Fu K, Ma X, Zhang Z, Chen W. Tumor necrosis factor in synovial fluid of patients with temporomandibular disorders. *J Oral Maxillofac Surg* 1995;53:424-6.
- Kubota E, Kubota T, Matsumoto J, Shibata T, Murakami KI. Synovial fluid cytokines and proteinases as markers of temporomandibular joint disease. *J Oral Maxillofac Surg* 1998;56:192-8.
- Sandler NA, Buckley MJ, Cillo JE, Braun TW. Correlation of inflammatory cytokines with arthroscopic findings in patients with temporomandibular joint internal derangements. *J Oral Maxillofac Surg* 1998;56:534-43.
- Nordahl S, Alstergren P, Kopp S. Tumor necrosis factor-alpha in synovial fluid and plasma from patients with chronic connective tissue disease and its relation to temporomandibular joint pain. *J Oral Maxillofac Surg* 2000;58:525-30.
- Perdue MH, Masson S, Wershil BK, Galli SJ. Role of mast cells in ion transport abnormalities associated with intestinal anaphylaxis. Correction of the diminished secretory response in genetically mast cell-deficient W/W<sup>v</sup> mice by bone marrow transplantation. *J Clin Invest* 1991;87:687-93.
- Quinn JH, Bazan NG. Identification of prostaglandin E<sub>2</sub> and leukotriene B<sub>4</sub> in the synovial fluid of painful, dysfunctional temporomandibular joints. *J Oral Maxillofac Surg* 1990;48:968-71.
- Alstergren P, Kopp S. Prostaglandin E<sub>2</sub> in temporomandibular joint synovial fluid and its relation to pain and inflammatory disorders. *J Oral Maxillofac Surg* 2000;58:180-6.

36. Dijkgraaf LC, Liem RS, de Bont LG. Ultrastructural characteristics of the synovial membrane in osteoarthritic temporomandibular joints. *J Oral Maxillofac Surg* 1997;55:1269-79.
37. Keat A, Thomas B, Hughes R, Taylor-Robinson D. *Chlamydia trachomatis* in reactive arthritis. *Rheumatol Int* 1989;9:197-200.
38. Kingsley G, Sieper J. Current perspectives in reactive arthritis. *Immunol Today* 1993;14:387-91.
39. Rahman MU, Cheema MA, Schumacher HR, Hudson AP. Molecular evidence for the presence of *Chlamydia* in the synovium of patients with Reiter's syndrome. *Arthritis Rheum* 1992;35:521-9.
40. Taylor-Robinson D, Gilroy CB, Thomas BJ, Keat AC. Detection of *Chlamydia trachomatis* DNA in joints of reactive arthritis patients by polymerase chain reaction. *Lancet* 1992;340:81-2.
41. Hammer M, Nettelbreker E, Hopf S, Schmitz E, Porschke K, Zeidler H. Chlamydial rRNA in the joints of patients with Chlamydia-induced arthritis and undifferentiated arthritis. *Clin Exp Rheumatol* 1992;10:63-6.
42. Milam SB, Zardeneta G, Schmitz JP. Oxidative stress and degenerative temporomandibular joint disease: A proposed hypothesis. *J Oral Maxillofac Surg* 1998;56:214-23.

*Reprint requests:*

Charles H. Henry, DDS  
650 Court St  
Keene, NH 03431  
chenry@pol.net