

A Comparison of Serratus Anterior Muscle Activation During a Wall Slide Exercise and Other Traditional Exercises

Dustin H. Hardwick, DPT¹

Justin A. Beebe, MSPT¹

Mary Kate McDonnell, PT, DPT, OCS²

Catherine E. Lang, PT, PhD^{2,3}

Study Design: Single-group repeated-measures design.

Objectives: To investigate the ability of the wall slide exercise to activate the serratus anterior muscle (SA) at and above 90° of humeral elevation.

Background: Strengthening of the SA is a critical component of rehabilitation for patients with shoulder impingement syndromes. Traditional SA exercises have included scapular protraction exercises such as the push-up plus. These exercises promote activation of the SA near 90° of humeral elevation, but not in positions above 90° where patients typically experience pain.

Methods and Measures: Twenty healthy subjects were studied performing 3 exercises: (1) wall slide, (2) plus phase of a wall push-up plus, and (3) scapular plane shoulder elevation. Three-dimensional position of the thorax, scapula, and humerus and muscle activity from the SA, upper and lower trapezius, and latissimus dorsi were recorded. The magnitudes of activation for each muscle at 90°, 120°, and 140° of humeral elevation were quantified from EMG records. Repeated-measures analyses of variance were used to determine the degree to which the different exercises activated the SA at the 3 humeral positions.

Results: The intensity of SA activity was not significantly different between the 3 exercises at 90° of humeral elevation ($P = .40$). For the wall slide and scapular plane shoulder elevation exercises, SA activity increased with increasing humeral elevation angle ($P = .001$), with no significant differences between the 2 exercises ($P = .36$).

Conclusion: The wall slide is an effective exercise to activate the SA muscle at and above 90° of shoulder elevation. During this exercise, SA activation is not significantly different from SA activation during the push-up plus and scapular plane shoulder elevation, 2 exercises previously validated in the literature. *J Orthop Sports Phys Ther* 2006;36(12):903-910. doi:10.2519/jospt.2006.2306

Key Words: electromyography, scapula, shoulder

¹ PhD student in Movement Science, Program in Physical Therapy, Washington University, St. Louis, MO.

² Assistant Professor, Program in Physical Therapy and the Department of Orthopedics, Washington University, St. Louis, MO.

³ Assistant Professor, Program in Occupational Therapy and the Department of Neurology, Washington University, St. Louis, MO.

This study was approved by the Washington University School of Medicine Human Studies Committee and supported by NIH HD047669 (CEL).

Address correspondence to Catherine E. Lang, Program in Physical Therapy, Washington University, 4444 Forest Park Blvd, Campus Box 8502, St. Louis, MO 63108. E-mail: langc@wustl.edu

It is well-accepted that appropriate activation of the serratus anterior muscle is important in the maintenance of a normal scapulo-humeral rhythm during elevation of the arm.^{2,4,15} As the humerus is elevated, the serratus anterior assists in upwardly rotating and posteriorly tipping the scapula and prevents scapular winging by keeping the scapula flat on the thorax.^{2,4,15} Impaired serratus anterior activation has been associated with altered scapular kinematics and has been suggested as one mechanism underlying shoulder impingement syndromes.^{9,12} Impaired serratus anterior activation may also lead to compensatory overactivation of synergists, namely the trapezius.^{9,14} This may lead to further scapular kinematic faults, including excessive scapular elevation, potentially contributing further to impingement symptoms.^{9,14} Thus, strengthening the serratus anterior is often considered a critical component of rehabilitation for patients with shoulder impingement syndromes.

Various exercises to strengthen the serratus anterior have been investigated.^{1,5,8,11,13,14} Examples

include forward-punch exercises, dynamic-hug exercise, weight-resisted elevations of the humerus, and the push-up plus.^{1,5,8,11,13,14} The plus phase of the push-up plus refers to the posterior translation of the thorax on a fixed scapula, resulting in scapular protraction. This can be done alone, or following a traditional push-up. The push-up plus has many variations that can take advantage of full or partial gravity, making it relatively easy to adapt to a variety of patients. Because of the fixed position of the arms on the wall or on the floor, the push-up plus activates and strengthens the serratus anterior only up to 90° of humeral elevation.¹³ While theoretically possible, the push-up plus has never been investigated at humeral elevation angles above 90°. Other studies, however, have demonstrated that the altered scapular kinematics during humeral elevation do not occur at this mid range, but rather at higher elevation angles.^{9,12} Thus, alternative exercises that can activate and strengthen the serratus anterior in humeral positions above 90° may be beneficial in the rehabilitation of patients with shoulder impingement syndromes.

The purpose of this study was to investigate how an alternative exercise, the wall slide, activated the serratus anterior. The wall slide exercise is not a new exercise,¹⁷ but is used less often in the clinic than the push-up plus and its variations. A potential advantage of the wall slide is that execution of the wall slide requires elevation of the humerus well above the 90° position used in the push-up plus exercise. We therefore compared activation of the serratus anterior during the wall slide to the plus phase of the push-up plus against the wall and to scapular plane shoulder elevation using surface electromyography (EMG). Upper and lower trapezius muscle activity was also recorded because increased activity in those muscles has been identified in individuals with shoulder impingement syndromes.⁹ We hypothesized that the wall slide exercise would activate the serratus anterior as effectively as the push-up plus exercise against the wall, but would do so at humeral elevation angles above 90°.

METHODS

Subjects

Twenty healthy, right-handed adults (10 males and 10 females; age range, 23-41 years) participated in this study. Subjects were recruited by word of mouth from the School of Medicine student body. Subjects were assessed by self-report to be free of current or recent history of orthopedic or neurological problems in their upper extremities. This study was approved by the Human Studies Committee at Washington University School of Medicine and all subjects provided informed consent prior to participation.

Paradigm

Subjects were tested during a single session that was approximately 1 hour in duration. All data were collected from the right side of the body while subjects were standing. An electromagnetic system (Motion Monitor, Innovative Sports Training Inc, Chicago, IL) was used to collect 3-dimensional movement of the thorax, scapula, and humerus, according to the International Society of Biomechanics, Shoulder Group Recommendations.¹⁹ Sensors were placed on the sternum, the flat superior aspect of the acromion, and the distal humerus.^{13,19} Sensors and trailing wires were secured with tape so that movement of the wires could not result in arbitrary sensor movement. The humeral sensor was additionally secured with self-adhesive Coban to further limit skin movement. With arms relaxed, bony landmarks on the thorax, scapula, and humerus were digitized with a custom probe to permit transformation of sensor data into local segment coordinates.¹⁹

Surface EMG was collected from the serratus anterior, latissimus dorsi, and upper and lower trapezius muscles using the Myopac system (Run Technologies, Laguna Hills, CA) at a bandwidth of 10 to 1000 Hz, impedance of 1 M Ω , CMRR of 90 dB min at 60 Hz. The serratus anterior was the primary muscle of interest. The latissimus dorsi was recorded to rule out crosstalk from that muscle detected by the electrode on the serratus anterior. Silver-silver chloride bipolar electrodes (VerMed, Bellows Falls, VT) were placed on (1) the lower serratus anterior muscle fibers,¹⁶ below the axilla and anterior to the latissimus dorsi parallel to the muscle fibers over the sixth or seventh rib, with the shoulder flexed to 90°, (2) the latissimus dorsi, inferior and lateral to the inferior angle of the scapula, (3) the upper trapezius, midway between the acromion and the cervical spine, and (4) the lower trapezius, just inferior and medial to the inferior angle of the scapula. The ground electrode was placed on the ipsilateral ankle. Electrodes were 12 mm in diameter. Interelectrode distance was varied between 7 and 12 mm, depending on the muscle being recorded, to obtain the largest possible signal with the least amount of noise from the underlying muscle.⁷ EMG signals were amplified by a factor of 2000 to 5000 to produce a signal that fell within a ± 5 -V range during a maximum voluntary isometric muscle contraction. Electrode wires were taped to the skin to prevent artifacts resulting from moving wires. Each EMG signal was visually inspected on an oscilloscope during resisted contractions of each of the 4 muscles (using modified manual muscle testing positions⁶) prior to data collection to ensure an adequate signal-noise ratio and to minimize crosstalk from adjacent or underlying muscles. Given that the rhomboids lie in close proximity to the lower trapezius, it

is likely that the lower trapezius electrode recorded some rhomboid activity. Kinematic and EMG data were simultaneously collected at 100 and 1000 Hz, respectively.

Prior to performing the selected exercises, a maximum voluntary isometric contraction (MVIC) of the serratus anterior was recorded during a manual muscle test in the position described by Kendall.⁶ Subsequently, each subject performed the 3 selected movements: scapular plane shoulder elevation, wall slide exercise, and the push-up plus against the wall. For scapular plane shoulder elevation, subjects started with arms at their sides with palms facing the body and thumbs up. They were instructed to raise both arms together at an angle approximating the plane of the scapula, for this study defined as 30° anterior to the frontal plane.¹⁰ To maintain a consistent plane of arm elevation, subjects stood facing a wall and were asked to brush the wall with their fingertips as they raised their arms. The end of the movement was when subjects obtained their maximal shoulder elevation. For the wall slide exercise (Figure 1), subjects stood facing a smooth wall with the dominant foot against the base of the wall and with the opposite foot shoulder-width apart and behind the dominant foot. The start position was with the ulnar border of the forearms in contact with the wall, and the shoulders and elbows at 90°. The shoulders were elevated in a plane approximating the scapular plane. The subjects were instructed to slide the forearms up the wall, while leaning into it by transferring body weight from the nondominant foot to the dominant foot. The staggered-foot position was used because it helps patients to shift their weight forward as they slide their forearms up the wall. Subjects were verbally cued to “bring your shoulder blades out and around as you slide up the wall”; this verbal cue was an attempt to promote normal scapular movement. The end of the movement was when subjects obtained their maximal shoulder elevation. For the push-up plus, we tested the plus phase of the wall version because this is the phase of the exercise that produces the maximum serratus anterior activation.¹¹ Subjects stood facing the same wall with feet even and shoulder-width apart. The start position was with the palms of the hands flat against the wall, elbows extended but not locked, shoulders elevated to approximately 90°, and the trunk leaning toward the wall. They started with the thorax sagged towards the wall, resulting in scapular retraction. Subjects were instructed to use their shoulder blades to posteriorly translate their body on their arms, resulting in scapular protraction. We chose to evaluate the plus phase against partial gravity (ie, on the wall) because this is often the only variation in which many of our patients with shoulder pain can perform early on in the rehabilitation process.

Subjects were asked to perform each exercise at a self-selected pace and the velocity of movement during each exercise was not controlled. We did not control for velocity of movement because we wanted to mimic the conditions under which these exercises are most likely to be performed in a clinical setting. Subjects practiced each movement prior to recording until they could execute it correctly. This typically took only 1 or 2 practice trials. Three trials of each movement were recorded and stored offline for further analyses.

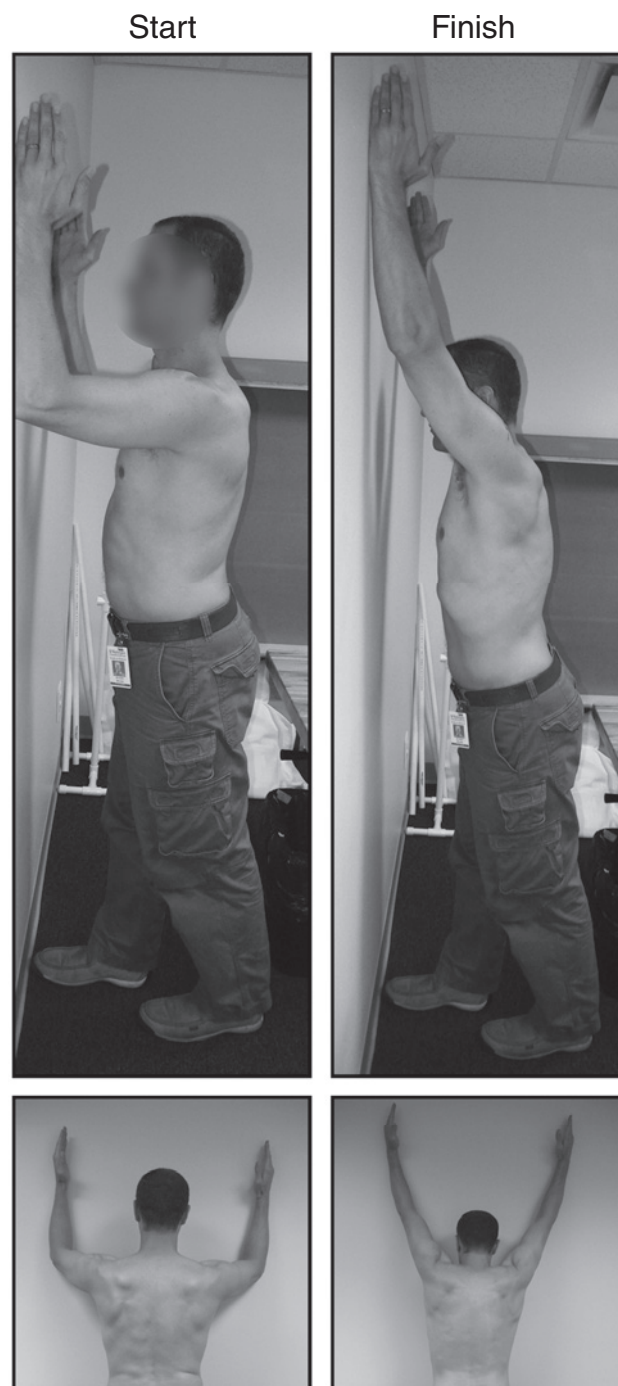


FIGURE 1. Lateral and posterior views of the start and end positions for the wall slide exercise.

Analyses

Motion Monitor software (Innovative Sports Training Inc, Chicago, IL) was used to extract position and angle data. Custom-written software in MATLAB (The Mathworks, Natick, MA) was used for all other data processing. Kinematic data were low-pass filtered at 6 Hz, with a zero-phase-lag (MATLAB `filtfilt` function), second-order Butterworth filter.¹⁸ The main kinematic variable used in this study was humeral elevation. Humeral elevation was defined as the elevation angle of the humerus with respect to the thorax (ie, the x component of the y - x - y Euler sequence).¹⁹ For ease of communication, the humeral elevation angles were transformed so that when the arm is hanging straight down by the side, humeral elevation angles approach 0°, when the arm is directly overhead, values approach 180°. Humeral elevation angles for each trial were used to find the times at which the humerus was at 90°, 120°, and 140° of elevation.

EMG data were full-wave rectified. Data were then low-pass filtered at 20 Hz, with a zero-phase-lag, second-order Butterworth filter to obtain a linear envelope for extracting the magnitude (amount) of muscle activation.¹⁸ For each muscle and for each trial, the magnitude of activation was obtained by averaging the smoothed EMG signal during a 50-ms window (fixed duration from 25 ms before to 25 ms after obtaining target humeral angle) when the humerus reached the 90°, 120°, and 140° elevation angles. For the push-up plus against the wall trials, the humeral elevation typically varied between 90° and 100°, and thus, only a single value was obtained when the subject approached full scapular protraction. Values extracted from the 3 recorded trials of each movement were averaged and used to represent the amount of activity for a given muscle and a given movement in each subject. For the purpose of statistical analysis, the magnitude of activation is expressed in volts. Although it is often reported in other studies of therapeutic exercises,^{1,3,11,13} we chose not to normalize EMG activity as a percent of MVIC for our analyses. We made this decision based on 3 reasons: (1) EMG activity in this study was recorded during a single session with a single placement of electrodes on each muscle, (2) between-subjects differences in muscle activation could be controlled for using a repeated-measures design, and (3) previous reports and our own pilot testing of various test positions to elicit MVICs for each muscle indicate that there is not a clear choice as to which positions should be used and why.^{1,3,9,11} In the Table, we also report EMG activation as a percentage of MVIC for the purpose of comparison with other studies.

Statistical analyses were done with Statistical software (Statsoft, Inc, Tulsa, OK). After approximately

TABLE. Serratus anterior muscle activation during 3 movements. Values are means (SD).

	Scapular Plane Shoulder Elevation	Wall Slide	Push-up Plus
Absolute value (V) at:			
90°	0.499 (0.293)	0.498 (0.469)	0.398 (0.338)
120°	0.716 (0.512)	0.745 (0.779)	–
140°	1.009 (0.826)	0.840 (0.728)	–
% MVIC*			
90°	41.1 (28.5)	37.1 (22.9)	31.3 (35.1)
120°	55.1 (40.0)	58.3 (43.0)	–
140°	82.4 (77.1)	75.7 (66.5)	–

*MVIC, maximum voluntary isometric contraction, obtained during a manual muscle test.

half of the data were collected, a power analysis was done to calculate the number of subjects needed to determine a clinically meaningful difference between movements. What constitutes a clinically meaningful difference in EMG voltage is not known. For this study, we set the minimal value of clinically meaningful difference at 0.20 V. This value was chosen because, after the first half of data collection, a change of 0.20 V was equal to a change of 10% MVIC of the serratus anterior. The number of subjects was estimated to be 20 to detect a true 0.20-V difference between the average serratus anterior activations at 90° for the 3 movements, using a standard deviation of 0.41 V, 90% power, and a 2-tailed level of significance of 0.05.

Variables were normally distributed as determined by Kolmogorov-Smirnov tests, thus parametric statistics were used. The first null hypothesis tested was that there would be no difference in muscle activation between the 3 movements at 90° of humeral elevation. To test this hypothesis, repeated-measures analyses of variance (ANOVAs) with 1 within-subject factor (movement) was used to compare muscle activations at 90° of humeral elevation. The second null hypothesis tested was that there would be no differences in muscle activation at different humeral elevation angles, nor between the 2 different movements in which humeral elevation occurred. To test this hypothesis, repeated-measures ANOVAs with 2 within-subject factors (movement: wall slide and scapular plane shoulder elevation; humeral angle: 90°, 120°, and 140°) were used. Because the push-up plus exercise does not involve humeral elevation much above 90°, it was not included in this second analysis. When significant effects were found with the ANOVAs, post hoc t tests with Bonferroni corrections for multiple comparisons were used to determine where the differences existed, where the corrected

critical *P* value depended on the number of comparisons. Values in the text are means \pm SD unless otherwise indicated.

RESULTS

An example of how a typical subject activated the muscles in each movement is shown in Figure 2. For scapular plane shoulder elevation (Figure 2A), this subject activated the serratus anterior and the upper trapezius initially, with the lower trapezius activated later. The amount of serratus anterior activation increased as the humeral elevation angle increased. For the wall slide (Figure 2B), this subject activated the serratus anterior, as well as the upper and lower trapezius muscles. Similar to scapular plane shoulder elevation, the serratus anterior activation increased with increasing humeral elevation. For the push-up plus against the wall (Figure 2C), the serratus anterior was activated to a similar degree as in the other 2 movements in this subject. The upper trapezius was activated only early in the movement and the lower trapezius was not activated much above resting levels. For all 3 movements, the latissimus dorsi was relatively quiescent.

Our main finding is that serratus anterior muscle activity (Figure 3A) was not significantly different between the 3 movements at 90° of humeral elevation ($F_{2,38} = 0.944$, $P = .40$). For the wall slide and scapular plane shoulder elevation movements, serratus anterior muscle activity increased with increasing humeral elevation angle (main effect of angle: $F_{2,34} = 13.30$, $P < .0001$), with no significant differences between the 2 movements (main effect of movement: $F_{1,17} = 0.87$, $P = .36$) and no significant interactions (angle \times movement: $F_{2,34} = 2.29$, $P = .12$). Post hoc testing on the main effect of angle indicated that activation at 120° ($P = .03$) and 140° ($P < .0001$) were greater than the activation at 90°. The Table presents the serratus anterior activation expressed in volts and expressed as a percentage of the MVIC for ease of comparison with other studies.

As expected, the magnitude of latissimus dorsi activity (Figure 3B) was minimal overall. At 90° of humeral elevation, latissimus dorsi activation was not significantly different in each of the 3 movements ($F_{2,38} = 0.04$, $P = .96$). Means \pm SDs for the 3 movements were 0.131 ± 0.142 V, 0.134 ± 0.102 V, and 0.129 ± 0.139 V for the wall slide, scapular plane shoulder elevation, and push-up plus against the wall movements, respectively. For the wall slide and scapular plane shoulder elevation movements, latissimus dorsi activity increased slightly with increasing humeral elevation angles (main effect of angle: $F_{2,34} = 7.71$, $P = .002$) with no significant differences between the 2 movements (main effect of movement: $F_{1,17} = 3.57$, $P = .08$) and no significant interactions

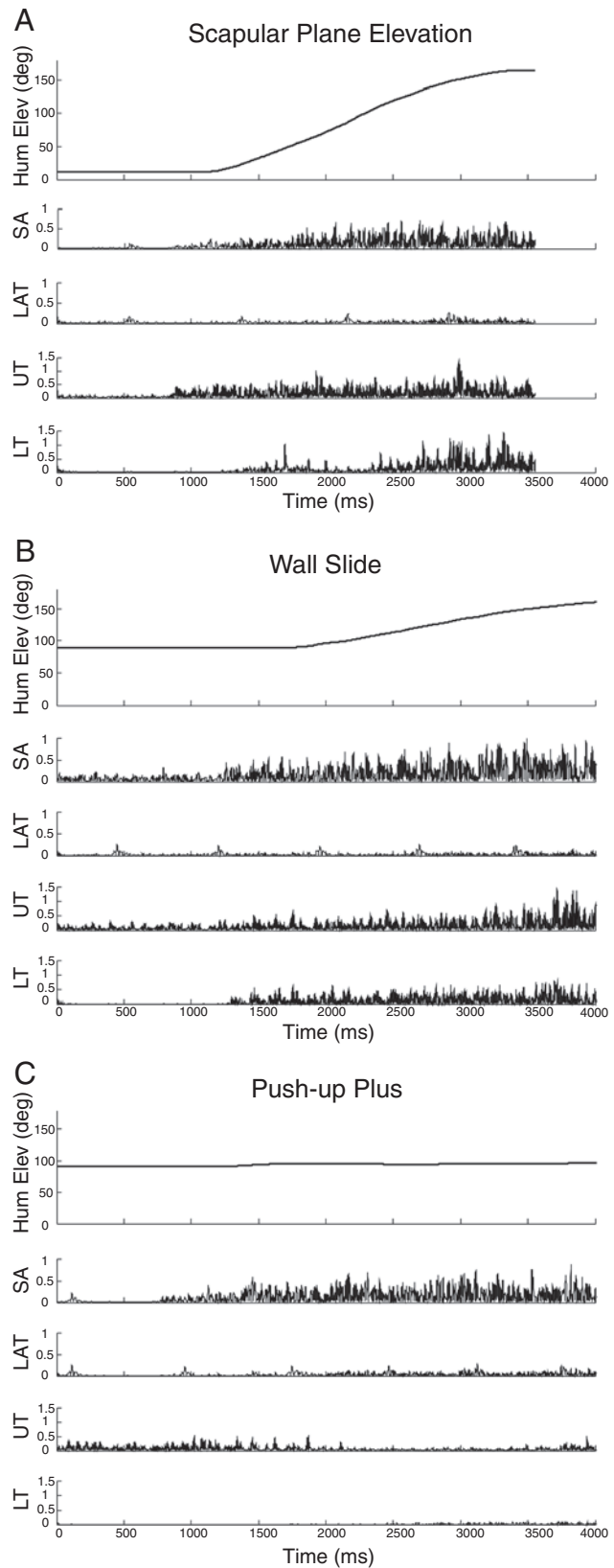


FIGURE 2. Examples of angle and rectified EMG traces during a single trial of scapular plane shoulder elevation (A), the wall slide exercise (B), and the push-up plus exercise (C). Y-axis units for muscle activity are volts. Abbreviations: Hum Elev, humeral elevation angle; LAT, latissimus dorsi; LT, lower trapezius; SA, serratus anterior; UT, upper trapezius.

(angle \times movement: $F_{2,34} = 0.01$, $P = .99$). Post hoc testing on the main effect of angle indicated that activation at 140° was greater than activations at 90° and 120° ($P = .001$).

The upper trapezius (Figure 3C) was activated more in the wall slide (0.534 ± 0.566 V) and scapular plane shoulder elevation (0.547 ± 0.688 V) movements than in the push-up plus against the wall movement (0.211 ± 0.291 V) at 90° of humeral elevation ($F_{2,38} = 11.20$, $P = .0002$; post hoc: push-up plus against the wall different than the other 2 movements). Comparison of activation at increasing humeral angles showed a significant interaction effect (angle \times movement: $F_{2,38} = 4.863$, $P = .01$). Post hoc tests indicated that upper trapezius activation was greater at 120° of humeral elevation compared to 90°

during the wall slide movement ($P = .015$) but not during the scapular plane shoulder elevation movement ($P = .99$).

Activation of the lower trapezius (Figure 3D) was not significantly different between the wall slide (0.118 ± 0.177 V), scapular plane shoulder elevation (0.133 ± 0.167 V), and the push-up plus against the wall (0.032 ± 0.028 V) movement ($F_{2,38} = 3.187$, $P = .053$). With increasing humeral elevation angles, lower trapezius activity increased in the scapular plane shoulder elevation movement but not in the wall slide movement (angle \times movement interaction: $F_{2,34} = 5.639$, $P = .007$). Post hoc testing indicated that lower trapezius activation was greater at 140° than at 90° ($P = .007$) in the scapular plane shoulder elevation movement only.

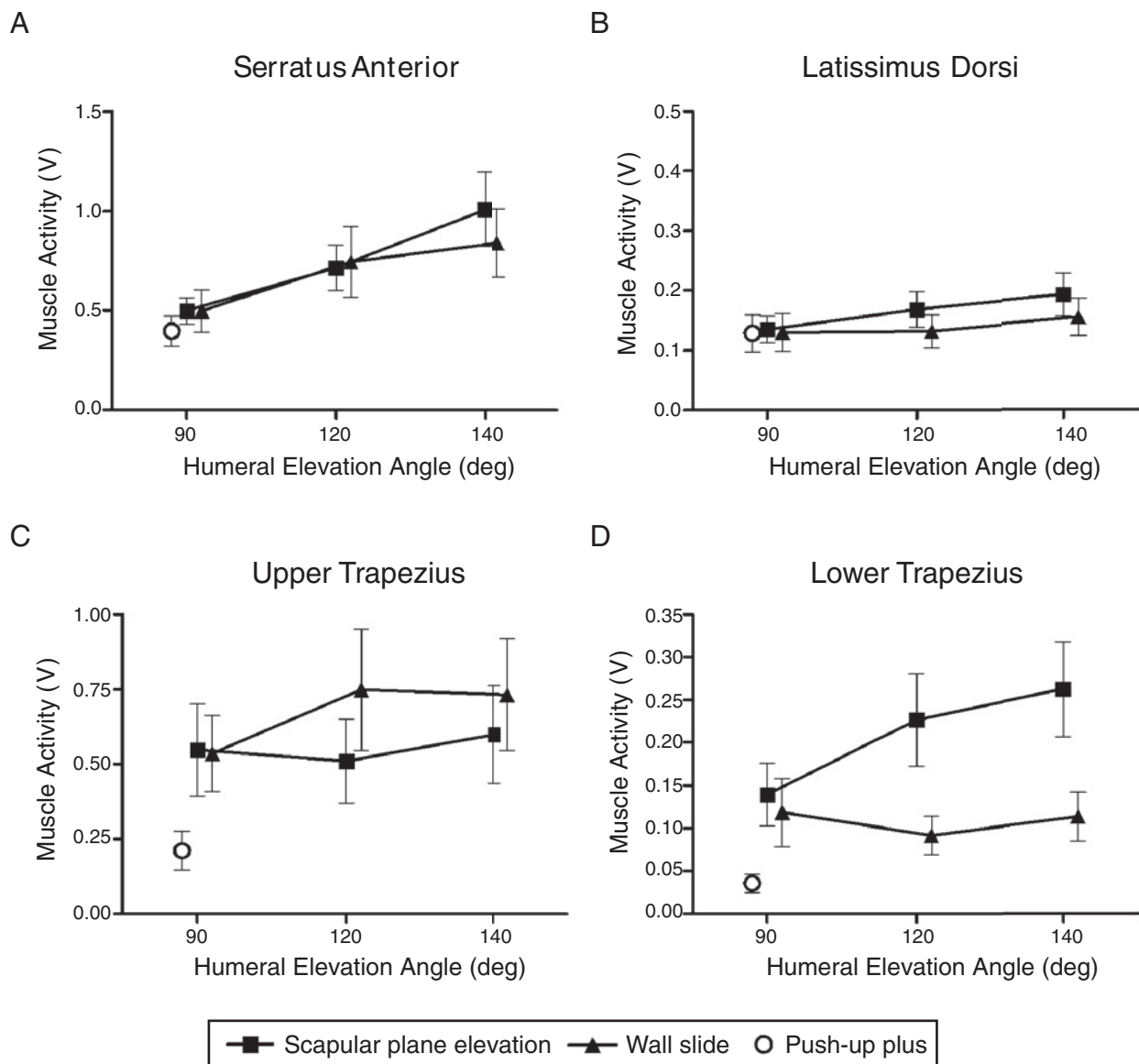


FIGURE 3. Serratus anterior (A), latissimus dorsi (B), upper trapezius (C), and lower trapezius (D) muscle activation for each movement. Values are means \pm SE.

DISCUSSION

We found that serratus anterior muscle activity was not significantly different between each of the 3 movements at 90° of humeral elevation. As the angle of humeral elevation increased, serratus anterior activation during the wall slide exercise and the scapular plane shoulder elevation movement increased. These data support our hypothesis that the wall slide exercise activates the serratus anterior as effectively as the plus phase push-up-plus exercise performed against the wall, and perhaps more importantly, can achieve this activation in positions above 90° of humeral elevation. For patients with shoulder impingement syndromes with presumed weakness of the serratus anterior, activation of the serratus anterior muscle above 90° may be important because this is where the altered scapular kinematics have been described by some investigators,^{9,12} and where painful symptoms are frequently experienced.

Methodological Issues

The fact that the wall slide exercise activated the serratus anterior as well as the push-up plus performed against the wall implies that incorporating the wall slide into the rehabilitation of patients with shoulder impingement syndromes could be beneficial. We note, however, 2 limitations with our paradigm that need to be considered. First, we studied a homogeneous sample of young, healthy adults. It is possible that any of the 3 exercises are not as effective in activating the serratus anterior in older populations or in patients with shoulder dysfunction. Although others have previously demonstrated that individuals with mild shoulder dysfunction showed similar activation patterns during the performance of various therapeutic exercises,¹¹ further studies comparing muscle activations in patients with shoulder pathology are needed.

Second, we studied the plus phase of the modified push-up plus exercise where the individual leans into the wall (against partial gravity). Compared to the wall version, the traditional floor version of the push-up plus activates the serratus anterior about 50% more in the plus phase.¹¹ Thus, it is likely that the wall slide exercise would have activated the serratus anterior less than the plus phase of the push-up plus if we had studied the floor version of that exercise. We chose the wall version because the majority of our patients with shoulder dysfunction can do this exercise successfully but cannot do the floor version. Comparison of the wall version of the push-up plus with the version of the wall slide described here is appropriate as both versions represent the initial modification in their respective progression from easiest to hardest. As serratus anterior activation and strength improve, the floor version of the push-up-plus exercise may be an appropriate

choice to sufficiently activate the serratus anterior.⁸ We speculate, however, that a Thera-Band version of the wall slide exercise might also be appropriate because it could potentially require greater serratus anterior activation above 90° of humeral elevation.

A Comparison of the 3 Exercises

Our study is not the first to investigate an exercise that activates the serratus anterior above 90° of shoulder flexion. Shoulder elevation in the plane of the scapula above 120° using a hand weight maximally activated the serratus anterior.³ Likewise, serratus anterior activation was high during shoulder elevation exercises from 120° to 150° of shoulder flexion.¹⁴ Our results complement these reports, as we found similar magnitudes of serratus anterior activation during the scapular plane shoulder elevation and wall slide exercises. We hypothesize that a potential advantage of the wall slide exercise as described here is that it could be implemented earlier in the rehabilitation process than other shoulder abduction and elevation exercises studied previously because, anecdotally, patients report that it is less painful to perform. Further studies are required to test this speculation.

We found that the upper trapezius was activated more during the wall slide and scapular plane shoulder elevation exercises than during the push-up plus against the wall. This could be because the wall slide and scapular plane shoulder elevation exercises require scapular elevation for proper performance, with the upper trapezius being a primary agonist for this motion. Others have hypothesized that excess upper trapezius activity is unfavorable because it has been linked to abnormal scapular kinematics in patients with shoulder impingement syndromes, and it has been viewed as a compensatory strategy for moving the scapula in the presence of weak serratus anterior activation.^{9,12,13,16} We find it important to note that some amount of upper trapezius activity is expected and is desirable because the upper trapezius works synergistically with the serratus anterior to provide the necessary upward rotation and elevation of the scapula during humeral elevation.¹⁵ During rehabilitation of patients with shoulder impingement syndromes, the challenge may therefore be to discourage compensatory or exaggerated shoulder shrugging types of movements while still encouraging adequate scapular elevation and upward rotation during the performance of overhead activities.

We found that the lower trapezius activation increased with increasing humeral elevation angles during scapular plane shoulder elevation but not during the wall slide. This could be because, during scapular plane shoulder elevation, more lower trapezius activity is needed to support the load of the upper extremity. During the wall slide, the upper extremity is partially supported on the wall, making

additional lower trapezius activity potentially unnecessary.

Based on our data, it may be reasonable to choose the wall slide exercise if you wish to activate the serratus anterior in positions at and above 90° of humeral elevation, and wish to do so early in the rehabilitation process. If the patient has severe compensations of excess shoulder shrugging and excess upper trapezius activity, then the plus phase of the wall push-up plus may be a better choice as it elicited the least upper trapezius activation among the exercises we studied. Finally, if a clinician desires to elicit more lower trapezius activation in the patient, and the patient is able to perform unassisted shoulder flexion exercises, the scapular plane shoulder elevation exercise may be an appropriate choice, as it elicited more lower trapezius activity than the other exercises, while maintaining activity of the serratus anterior and upper trapezius.

This study is a first step in looking at the wall slide exercise. Future studies are needed to validate the effectiveness of the wall slide exercise in activating the serratus anterior in a patient population with subacromial impingement syndrome and to examine how a progression of the wall slide exercise (eg, adding Thera-Band resistance) might compare to the progression of exercises such as the push-up plus (eg, floor push-up plus). Studies are also needed to examine the force production capabilities of the serratus anterior before and after training with the wall slide exercise, as well as studies that examine the ability of a person to activate the serratus anterior during functional activities following training with the wall slide exercise, to see if it has an effect in motor retraining.

CONCLUSION

The wall slide appears to be an appropriate exercise for activating the serratus anterior in positions at and above 90° of shoulder elevation. The amount of serratus anterior activation during the wall slide exercise is not significantly different than the amount of serratus anterior activation during the plus phase of the wall push-up plus exercise. The wall slide exercise, however, allows for this activation overhead, where patients with shoulder impingement have been shown to have altered scapular mechanics and decreased serratus anterior activity.⁹ Furthermore, this exercise may be appropriate to initiate early in the rehabilitation process because the wall slide provides some support to the upper extremity.

REFERENCES

1. Decker MJ, Hintermeister RA, Faber KJ, Hawkins RJ. Serratus anterior muscle activity during selected rehabilitation exercises. *Am J Sports Med.* 1999;27:784-791.
2. Ekstrom RA, Bifulco KM, Lopau CJ, Andersen CF, Gough JR. Comparing the function of the upper and lower parts of the serratus anterior muscle using surface electromyography. *J Orthop Sports Phys Ther.* 2004;34:235-243.
3. Ekstrom RA, Donatelli RA, Soderberg GL. Surface electromyographic analysis of exercises for the trapezius and serratus anterior muscles. *J Orthop Sports Phys Ther.* 2003;33:247-258.
4. Inman VT, Saunders JB, Abbott LC. Observations on the functions of the shoulder joint. *J Bone Joint Surg Am.* 1944;26A:1-30.
5. Kamkar A, Irrgang JJ, Whitney SL. Nonoperative management of secondary shoulder impingement syndrome. *J Orthop Sports Phys Ther.* 1993;17:212-224.
6. Kendall FP, McCreary EK, Provance PG. *Muscles: Testing and Function.* 4th ed. Baltimore, MD: Williams & Wilkins; 1993.
7. Lang CE, Schieber MH. Reduced muscle selectivity during individuated finger movements in humans after damage to the motor cortex or corticospinal tract. *J Neurophysiol.* 2004;91:1722-1733.
8. Lear LJ, Gross MT. An electromyographical analysis of the scapular stabilizing synergists during a push-up progression. *J Orthop Sports Phys Ther.* 1998;28:146-157.
9. Ludewig PM, Cook TM. Alterations in shoulder kinematics and associated muscle activity in people with symptoms of shoulder impingement. *Phys Ther.* 2000;80:276-291.
10. Ludewig PM, Cook TM, Nawoczenski DA. Three-dimensional scapular orientation and muscle activity at selected positions of humeral elevation. *J Orthop Sports Phys Ther.* 1996;24:57-65.
11. Ludewig PM, Hoff MS, Osowski EE, Meschke SA, Rundquist PJ. Relative balance of serratus anterior and upper trapezius muscle activity during push-up exercises. *Am J Sports Med.* 2004;32:484-493.
12. Lukasiewicz AC, McClure P, Michener L, Pratt N, Sennett B. Comparison of 3-dimensional scapular position and orientation between subjects with and without shoulder impingement. *J Orthop Sports Phys Ther.* 1999;29:574-583; discussion 584-576.
13. McClure PW, Bialker J, Neff N, Williams G, Karduna A. Shoulder function and 3-dimensional kinematics in people with shoulder impingement syndrome before and after a 6-week exercise program. *Phys Ther.* 2004;84:832-848.
14. Moseley JB, Jr., Jobe FW, Pink M, Perry J, Tibone J. EMG analysis of the scapular muscles during a shoulder rehabilitation program. *Am J Sports Med.* 1992;20:128-134.
15. Norkin C, Levangie P. *Joint Structure and Function. A Comprehensive Analysis.* Philadelphia, PA: F.A. Davis; 1983.
16. Peat M, Grahame RE. Electromyographic analysis of soft tissue lesions affecting shoulder function. *Am J Phys Med.* 1977;56:223-240.
17. Sahrmann SA. *Diagnosis and Treatment of Movement Impairment Syndromes.* St Louis, MO: Mosby; 2002.
18. Winter DA. *Biomechanics and Motor Control of Human Movement.* 2nd ed. New York, NY: Wiley-Interscience; 1990.
19. Wu G, van der Helm FC, Veeger HE, et al. ISB recommendation on definitions of joint coordinate systems of various joints for the reporting of human joint motion—Part II: shoulder, elbow, wrist and hand. *J Biomech.* 2005;38:981-992.