

# SYSTEMIC JOINT LAXITY (THE HYPERMOBILE JOINT SYNDROME) IS ASSOCIATED WITH TEMPOROMANDIBULAR JOINT DYSFUNCTION

DAVID HARINSTEIN, ROBERT B. BUCKINGHAM, THOMAS BRAUN, K. ORAL,  
DOROTHY H. BAUMAN, PAUL J. KILLIAN, and LEO P. BIDULA

**A consecutive series of 37 individuals admitted to the hospital for elective temporomandibular joint (TMJ) reconstructive surgery and 3 seen as outpatients with TMJ disease were evaluated for rheumatic disease or for another etiologic factor that might account for this problem. These 40 patients were screened by history, physical examination, and laboratory study. We soon noticed that many patients had generalized joint laxity. Eighteen of the first 40 individuals satisfied established criteria for the hypermobile joint syndrome. An additional 3 were found to have Ehlers-Danlos syndrome or a forme fruste of this disorder. Many were markedly hypermobile and could perform a number of flexible maneuvers. Although excessive joint laxity is known to be associated with a variety of rheumatic conditions, TMJ disease has not been recognized as one of them. No patient in this series had a systemic inflammatory disorder or any other apparent etiologic factor for TMJ**

**disease. We suggest that there is a cause-and-effect relationship between generalized joint laxity and TMJ disease.**

The temporomandibular joint (TMJ) is a ginglymoarthrodial joint, with both hinge and gliding movements. Its articular surfaces are covered with fibrocartilage rather than with hyaline cartilage. It is a complex joint, divided by a disc into 2 separate superior and inferior synovial spaces. Rotary motions of the joint occur mainly in the lower space, whereas anterior movement (which is referred to as translation) occurs mainly in the superior space.

The TMJ dysfunction syndrome refers to internal derangement of the joint, and is characterized by limitation of mandibular motion, joint "clicking" or crepitus, and preauricular pain (1). Other symptoms include headache, tinnitus, and earache. Early in the course of this disorder there may be no positive radiographic findings, but as time progresses, destruction of the intracapsular tissue becomes evident in some patients.

Myofascial pain dysfunction is a separate and distinct entity in which there is no demonstrable evidence of organic disease (1-3). The term is often confused with organic TMJ disease. It can be distinguished by the presence of tenderness of the muscles of mastication and the lack of tenderness of the joint with endaural palpation. There is no internal derangement in this disorder.

In most cases, the causes of organic TMJ dysfunction are not clear. Trauma has been identified as a causative factor in many cases, and bruxism and malocclusion with excessive joint loading are often contributing factors. One common finding in many

From Western Pennsylvania Hospital, Pittsburgh.

David Harinstein, MD: Resident in Internal Medicine; Robert B. Buckingham, MD: Attending Physician, Western Pennsylvania Hospital and Clinical Associate Professor of Medicine, University of Pittsburgh School of Medicine; Thomas Braun, PhD, DMD: Chairman, Department of Oral and Maxillofacial Surgery, Western Pennsylvania Hospital and Assistant Professor of Anatomy and Oral and Maxillofacial Surgery, University of Pittsburgh School of Dentistry; K. Oral, PhD, DMD: Director of Craniomandibular Disorders and Chief of Maxillofacial Prosthodontics; Dorothy H. Bauman, MD: Department of Radiology; Paul J. Killian, MD: Attending Physician, Western Pennsylvania Hospital and Clinical Assistant Professor of Medicine, University of Pittsburgh School of Medicine; Leo P. Bidula, MD: Attending Physician, Western Pennsylvania Hospital and Clinical Instructor in Medicine, University of Pittsburgh School of Medicine.

Address reprint requests to Robert B. Buckingham, MD, Suite GO2, Mellon Pavillion, 4815 Liberty Avenue, Pittsburgh, PA 15224.

Submitted for publication February 26, 1988; accepted in revised form May 9, 1988.

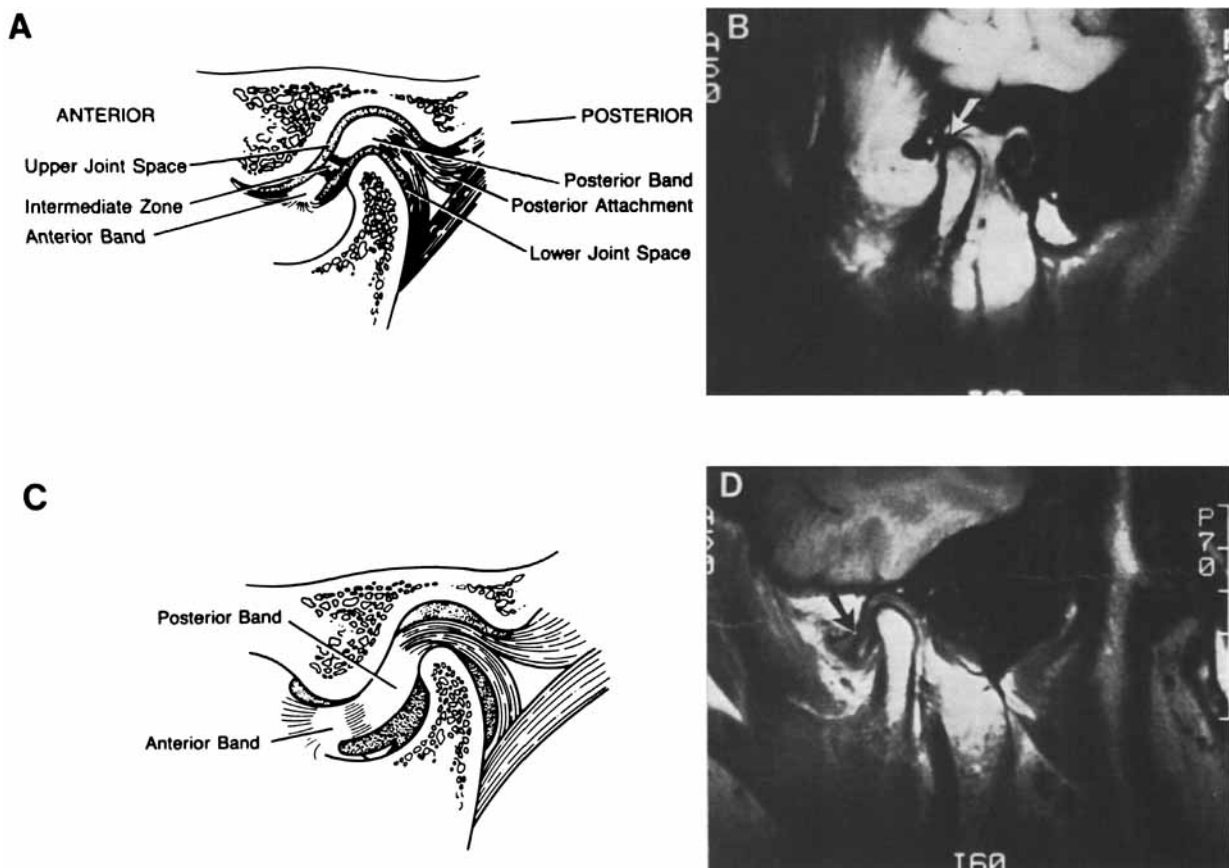
cases with no definable cause is anterior displacement of the disc. Normally, when the mouth is closed, the posterior band of the disc overlies the superior portion of the condyle. As the mouth opens, this posterior band moves posteriorly with respect to the condyle, as condylar rotation about the horizontal axis occurs. As the condyle moves anteriorly (or translates), the thin central portion of the disc becomes the articulating surface between the condylar head and the articular eminence of the temporal bone.

With abnormal disc displacement, the posterior band moves anteriorly from its normal position when the mouth is closed. Then when the mouth is opened, the condylar head impinges on the posterior band of the disc instead of rotating under the thin central zone (Figure 1). The condylar head crushes the disc against the temporal bone, and in the process of overcoming

this obstruction, causes crepitus. Clicking may occur with opening or closing or both.

In complete anteromedial dislocation of the disc, opening becomes limited ("closed lock"), and sounds may diminish. With time, the disc degenerates, and often the posterior ligamentous attachments perforate. It is at this point that crepitus becomes more evident than clicking. The pain that occurs may be a result of impingement of the condyle on the nerve fibers of the retrodiscal tissue.

Benign hypermobile joint syndrome (BHJS) is a disorder of increased joint laxity that is often hereditary (4-9). There are reports of increased familial prevalence. BHJS is found in 5-10% of white persons, and women greatly outnumber men with this condition. Ethnic differences in joint mobility have also been noted. Generalized joint laxity has been reported



**Figure 1.** The mandibular condyle, the mandibular fossa of the temporal bone, and the articular disc. **A**, Normal placement. The disc, which is connected at its circumference to the articular capsule and in front to the pterygoideus externus muscle, divides the joint into 2 separate articular cavities. **B**, Magnetic resonance image (MRI) of the same anatomic structures shown in **A**. **C**, An anteriorly displaced disc with the condyle impinging upon it. **D**, MRI of the same pathologic condition shown in **C**.

to occur in a high percentage in East Indian, Iraqi, and African populations (10). Often, joint hypermobility has been determined using grading systems that define and measure specific joint movements. These grading systems require fulfillment of a minimum of established criteria or are based on a numerical scoring system (9).

An association between excessive joint laxity and TMJ dysfunction has not been recognized. Despite this, there are a number of other musculoskeletal problems that occur in patients with hypermobile joints. Chondromalacia patellae (patellofemoral arthritis) and knee effusions, frequent ankle sprains and effusions, recurrent shoulder dislocations, sternoclavicular dislocations (or subluxations), and premature osteoarthritis may be seen (9). Mitral valve prolapse has been noted in association with BHJS, but this connection has not been firmly and unequivocally established (11). If cardiac valvular or other internal organ abnormalities are a part of the syndrome of increased joint laxity, then the disorder should be viewed as a systemic abnormality rather than a disorder localized to the joints.

## PATIENTS AND METHODS

**Patients.** The patient group consisted of 40 consecutively seen individuals who presented with TMJ dysfunction. Thirty-seven of these patients were admitted to the maxillofacial surgery service for the purpose of reconstructive surgery of the joint after conservative therapy had failed. The selection process, therefore, resulted in a group of patients with very severe disease. Three others were seen as outpatients, with TMJ clicking and pain as chief symptoms.

**Physical examination and medical history.** All patients were evaluated by a rheumatologist and by an oral surgeon. An evaluation form regarding hypermobile joint symptoms was developed to standardize the recording of results. Patients were also interviewed to determine if they had a rheumatic disease, a family history of rheumatic disease, a history of trauma, or any other feature known to be associated with joint problems. When indicated, appropriate laboratory studies were done.

**Criteria for assessment of hypermobility.** Joint hypermobility was assessed according to the criteria of Carter and Wilkinson (12), and also according to the modification of these criteria proposed by Beighton and coworkers (9,10), herein referred to as Beighton's criteria or Beighton's modification. These criteria are: 1) active hyperextension ( $>10^\circ$ ) of the elbows; 2) active hyperextension ( $>10^\circ$ ) of the knees; 3) passive hyperextension of the digits with parallel alignment of the digits and the dorsal forearm; 4) passive apposition of the thumb to the forearm; 5) passive and excessive dorsiflexion of the ankle and eversion of the foot; 6) ability to

touch the floor with the palms of the hands with the knees straight (Beighton's criterion).

The first 5 criteria are the criteria of Carter and Wilkinson (12). Beighton's criteria consist of numbers 1-4 and number 6; number 5 was eliminated for reasons to be discussed later. Fulfillment of 3 or more of the Carter and Wilkinson criteria, or a mobility score (10)  $\geq 4$  (see below), were considered to be consistent with BHJS. The mobility score was calculated using Beighton's criteria. One point was allocated for the ability to perform each of the 6 maneuvers, taking into account whether the finding was unilateral or bilateral. Thus, a patient received a score of 1 for unilateral elbow hyperextensibility, 2 for bilateral, etc. The data were, therefore, expressed in 2 ways: using the original 5 criteria of Carter and Wilkinson, and again using Beighton's modification.

The presence of loose skin, or any other feature suggesting a structural abnormality of a connective tissue macromolecule, supported the diagnosis of Ehlers-Danlos syndrome. Many of our patients with BHJS exhibited features of joint laxity that went far beyond the criteria of Carter and Wilkinson, or any of the modifications thereof.

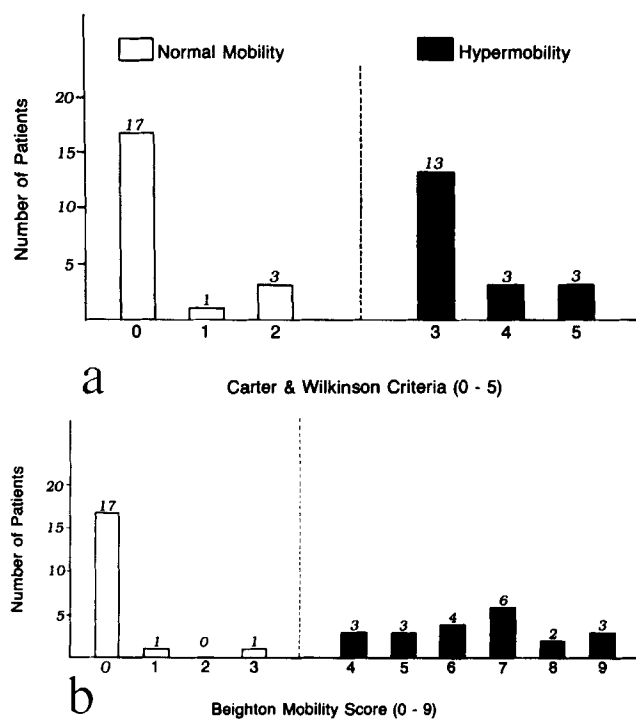
**Additional studies.** As a part of a complete evaluation of the TMJ abnormality, patients had routine roentgenograms, tomograms, and in many cases arthrograms, including cine recordings of motion. In a few cases, magnetic resonance imaging was done.

The tissue obtained at surgery was examined histopathologically, with routine hematoxylin and eosin staining and with collagen stains. No effort was made to study any of the tissues biochemically to define an abnormality at the molecular level.

## RESULTS

During the course of the study, 40 patients who exhibited TMJ disease were seen. Nineteen patients (47.5%) had joint hypermobility according to the Carter and Wilkinson criteria (Figure 2a), and 21 (52.5%) had joint hypermobility based on the Beighton scoring system (Figure 2b). Using Beighton's criteria, 21 (52.5%) had a mobility score  $\geq 4$ , and 15 (37.5%) had a score  $\geq 6$ . The age range of these patients was 17-56 years (mean 32). Nineteen patients did not have hypermobile joints. One, a man who had sustained a facial injury, had probably developed osteonecrosis of the mandibular condyle. No etiologic factor could be identified in the remaining 18 patients, who therefore were said to have idiopathic disease. The age range of the patients with idiopathic disease was 17-67 years (mean 36).

Of the 40 patients, tomograms were available for review in 12 with BHJS and in 14 without BHJS. The films were reviewed for reduced translation, joint hyperextension, and disc destruction (Table 1). The only radiographic difference between the 2 groups was



**Figure 2.** The number of patients with normal joint mobility and the number of patients with hypermobile joints who met **a**, 3 or more of the Carter and Wilkinson criteria (ref. 12), or **b**, 4 or more of the criteria described by Beighton et al (refs. 9 and 10).

joint hyperextension in 2 individuals with BHJS. In these patients, the condyle moved significantly anterior to the articular eminence on both sides. The radiologist was unaware which patients had or did not have joint hypermobility (systemic joint laxity) at the time of study of the films. These patients were all studied very late in the course of their disease. Earlier

**Table 1.** Prevalence of tomographic signs in 26 patients with temporomandibular joint (TMJ) disease\*

	Reduced translation	Joint hyperextension	Disc destruction
<b>BHJS</b>			
Left	8	2	7
Right	6	2	7
<b>Normal</b>			
Left	8	0	6
Right	9	0	8

\* Tomograms of the TMJ were available for review in 14 patients without and 12 patients with benign hypermobile joint syndrome (BHJS). All 26 patients had very severe, late-stage joint disease. The only difference noted was that 2 of the patients with BHJS had hyperextensible TMJs.

studies may have demonstrated differences not apparent in severely diseased joints.

In addition to the usual signs of joint laxity, we noted that many of these patients could perform other maneuvers or "tricks," and that many perceived themselves as double-jointed. Some could spontaneously dislocate their shoulders, sublux the hips, touch their elbows together behind the back, touch their heels together behind the neck, make spontaneous swan neck deformities with their fingers, sublux the first carpometacarpal joint, touch the tip of the tongue to the nose, and sit easily in the yoga position. Many of them had musculoskeletal symptoms, including aching and pain around the hypermobile joints, pain as a result of shoulder dislocation, frequent ankle sprains, knee pain, etc.

Three of the 21 patients had features suggestive of hereditary disorders of the connective tissue. Two had previously been told that they had Ehlers-Danlos syndrome, and a third had widespread telangiectasia, as well as well as marked joint hypermobility (Table 2). None of the patients encountered in this series had evidence of inflammatory arthritis of a systemic nature by history, physical examination, or laboratory study.

## DISCUSSION

Kirk and coworkers applied the term "hypermobility syndrome" to individuals with generalized joint laxity who presented with other musculoskeletal complaints (4). These complaints included widespread muscle and joint pains, sometimes associated with effusions. This connection was found in a series of 24 patients with hypermobile joints examined by Kirk et al over a 7-year period. As early as June 1967, at a meeting of the Heberden Society (4), during a question-and-answer period following the reading of their paper, which did not mention TMJ, Kirk and coworkers were asked, "Was there any evidence of discomfort or clicking in the temporomandibular joint?" The authors' answer was, "We received no complaints of this." The questioner, however, may have noticed the association years earlier.

Kirk and colleagues concluded that many individuals with joint hypermobility would develop premature degenerative disease in the cervical spine, the first carpometacarpal joint, and the patellofemoral joint. They emphasized the familial and hereditary nature of the disorder, but since there was no evidence in any of the patients of hyperelastic skin or any other abnormality of connective tissue, they concluded that

**Table 2.** Patients with features suggestive of hereditary disorders of the connective tissue

Patient	Age/sex	Previous diagnosis of Ehlers-Danlos	Beighton score*	Skin laxity	Other features
1	29/F	No	9	Yes	Telangiectasia, mitral valve prolapse
2	46/F	Yes	9	Yes	Mitral valve prolapse
3	38/F	Yes	9	Yes	Clubbed feet

\* See Patients and Methods and refs. 9 and 10 for explanation.

hypermobility was simply one extreme in a wide spectrum of joint mobility, and thus was "benign." They also discussed the possibility that hypermobility is a result of a hereditary disorder of connective tissue and represents a mild variant of Ehlers-Danlos syndrome, Marfan syndrome, and other established connective tissue diseases. Nevertheless, the term "benign hypermobile joint syndrome" is still used (6).

Although the term "hypermobility syndrome" was devised in 1967, a relationship between articular disease and generalized joint laxity had been pointed out years earlier. In 1958, Carter and Sweetnam (13) noted the association between familial joint laxity and recurrent dislocations of the patella, and in 1960, they noted the same association with dislocation of the shoulder (14); in 1964, Carter and Wilkinson reported the occurrence of persistent generalized joint laxity in some patients with congenital dislocation of the hip (12). Carter and Wilkinson examined 285 normal English schoolchildren, and found that excessive joint motion occurred in 7% (12). To do this, they set forth 5 criteria to be used in the determination of excessive joint laxity: the first 5 used by us in the present study. Their criteria appear to have been chosen quite arbitrarily, and reasons for the choices are not discussed. Nevertheless, these same criteria, or a modification of them, have been used in most subsequent studies of joint laxity.

The modification by Beighton and coworkers, proposed in 1973 (10), is probably the best system currently in use. These criteria include the assessment of joints in the upper and lower extremities as well as small and large joints, and also allow the assessment of trunk and hip movement. Measurements of composite joint motion (trunk and hip) are more likely to detect generalized joint laxity. In most cases, these criteria are based on a precisely measurable endpoint (i.e., apposition of the thumb to the forearm, placement of the palms on the floor, etc.) Excessive dorsiflexion of the ankle ( $>15^\circ$ ) and eversion of the foot, however, are

more difficult to measure, and for this reason Beighton and coworkers recommended eliminating this criterion.

Beighton and coworkers also believed that hyperextension of all of the fingers or of the middle finger inaccurately eliminated many patients, so they recommended changing this criterion to passive dorsiflexion of the little finger  $>90^\circ$ . Most authors recommend that 3 or more criteria be met to support a diagnosis of hypermobility, but Beighton et al assigned points to each criterion and required a minimum of 4 points. Using the point system, 2 criteria are sufficient to support a diagnosis of joint hypermobility, if the finding is present bilaterally. In a study of 502 normal African adults (10), it was found that 94% of men and 80% of women achieved scores of 0, 1, or 2. Several authors have noted an inverse relationship between joint laxity and age; joints become less mobile as people get older (9,10). The criteria used in our own study, we believe, are sufficiently rigorous to exclude normal individuals.

TMJ disease has not been recognized to be a complication of generalized joint laxity. One case of chronic TMJ subluxation in a 19-year-old man with an established diagnosis of Ehlers-Danlos syndrome has been reported (15). In 1981, Solberg suggested the possibility of a relationship between TMJ disease and systemic joint laxity (16), and Bates et al, in a preliminary study, suggested the presence of joint laxity in 11 of 15 women with internal derangements of the TMJ (17). Instead of conventional criteria for the diagnosis of joint laxity, Bates and coworkers used only elbow hyperextension and/or apposition of the thumb to the forearm ("wrist laxity"). The women's joints were said to be lax if 1 criterion was met.

Interestingly, Annandale (18) wrote of this subject in 1887: "... most modern works on surgery describe this affection as being generally due either to relaxation of the ligaments of the joint allowing a too free movement, or to inflammatory changes of a

simple, gouty or rheumatic nature." He also quoted an earlier work (19): "It is an affection occurring principally in delicate women, and has been thought to depend upon relaxation of the ligaments of the joint permitting a too free movement of the bone, and possibly (though this is a conjecture) a slipping of the interarticular cartilage." Long ago, these 2 observations suggested the possible importance of laxity of articular and/or intraarticular tissues in the etiology of TMJ disease.

Although the pathophysiologic mechanisms of joint hypermobility in these patients remain unclear, joint laxity may result from a disturbance in the normal relationships between the TMJ capsule, the bony architecture, and the associated musculoligamentous apparatus. If the functional relationships of this mechanical system are distorted, the position of the meniscus, relative to the condyle, may change and lead to progressive disc and ligament destruction and TMJ disease.

As the understanding of TMJ disease increases, the contribution of joint laxity should become clearer, and this new understanding may have an impact on future treatment decisions. Based on the findings presented in this study, we propose that joint laxity should be viewed as an etiologic factor in some patients with the temporomandibular joint dysfunction syndrome.

## REFERENCES

1. Foreman PA: Temporomandibular joint and myofascial pain dysfunction: some current concepts. 1. Diagnosis. 2. Treatment. *NZ Dent J* 81:47-57, 1985
2. Moss OA, Garret JC: Temporomandibular joint dysfunction syndrome and myofascial pain dysfunction syndrome: a critical review. *J Oral Rehabil* 11:3-28, 1984
3. Eversole LR, Machado L: Temporomandibular joint internal derangements and associated disorders. *J Am Dent Assoc* 110:69-79, 1985
4. Kirk JA, Ansell BM, Bywaters EGL: The hypermobility syndrome: musculoskeletal complaints associated with generalized joint hypermobility. *Ann Rheum Dis* 26:419-425, 1967
5. Grahame R, Jenkins JM: Joint hypermobility—asset or liability? A study of joint mobility in ballet dancers. *Ann Rheum Dis* 31:109-111, 1972
6. Jessee EF, Owen DS Jr, Sagar KB: The benign hypermobile joint syndrome. *Arthritis Rheum* 23:1053-1056, 1980
7. Horton WA, Collins DL, deSmet AA, Kennedy JA, Schimke RN: Familial joint instability syndrome. *Am J Med Genet* 6:221-228, 1980
8. Finsterbush A, Poggrund H: The hypermobility syndrome: musculoskeletal complaints in 100 consecutive cases of generalized joint hypermobility. *Clin Orthop* 168:124-127, 1982
9. Beighton P, Grahame R, Bird H: *Hypermobility of Joints*. Berlin, Springer-Verlag, 1983
10. Beighton P, Solomon L, Soskolne CL: Articular mobility in an African population. *Ann Rheum Dis* 32:413-418, 1973
11. Pitcher P, Grahame R: Mitral valve prolapse and joint hypermobility: evidence for a systemic connective tissue abnormality? *Ann Rheum Dis* 41:352-354, 1982
12. Carter C, Wilkinson J: Persistent joint laxity and congenital dislocation of the hip. *J Bone Joint Surg* 46B:40-45, 1964
13. Carter C, Sweetnam R: Familial joint laxity and recurrent dislocation of the patella. *J Bone Joint Surg* 40B:664-667, 1958
14. Carter C, Sweetnam R: Recurrent dislocation of the patella and of the shoulder. *J Bone Joint Surg* 42B:721-729, 1960
15. Goodman RM, Allison ML: Chronic temporomandibular joint subluxation in Ehlers-Danlos syndrome: report of case. *J Oral Surg* 27:659-661, 1969
16. Solberg WK: The troubled temporomandibular joint: new opportunities and challenges in research and clinical management. *Oro-Bio* 2(2), 1981
17. Bates RB, Stewart CM, Atkinson WB: The relationship between internal derangements of the temporomandibular joint and systemic joint laxity. *J Am Dent Assoc* 109:446-447, 1984
18. Annandale T: Displacement of the inter-articular cartilage of the lower jaw and its treatment by operation. *Lancet* I:411, 1887
19. Heath C: *Injuries and Diseases of the Jaws*. Third edition. London, Churchill, 1884