



Is tendon pathology a continuum? A pathology model to explain the clinical presentation of load-induced tendinopathy

J L Cook and C R Purdam

Br. J. Sports Med. 2009;43:409-416; originally published online 23 Sep 2008; doi:10.1136/bjsem.2008.051193

Updated information and services can be found at:
<http://bjsm.bmj.com/cgi/content/full/43/6/409>

These include:

References

This article cites 78 articles, 35 of which can be accessed free at:
<http://bjsm.bmj.com/cgi/content/full/43/6/409#BIBL>

1 online articles that cite this article can be accessed at:
<http://bjsm.bmj.com/cgi/content/full/43/6/409#otherarticles>

Rapid responses

You can respond to this article at:
<http://bjsm.bmj.com/cgi/eletter-submit/43/6/409>

Email alerting service

Receive free email alerts when new articles cite this article - sign up in the box at the top right corner of the article

Notes

To order reprints of this article go to:
<http://journals.bmj.com/cgi/reprintform>

To subscribe to *British Journal of Sports Medicine* go to:
<http://journals.bmj.com/subscriptions/>

Is tendon pathology a continuum? A pathology model to explain the clinical presentation of load-induced tendinopathy

J L Cook,¹ C R Purdam²

¹ Centre for Physical Activity and Nutrition Research, School of Exercise and Nutrition Sciences, Deakin University, Melbourne, Australia; ² Department of Physical Therapies, Australian Institute of Sport, Canberra, Australia

Correspondence to:
Dr Jill Cook, 221 Burwood Highway, Melbourne 3025, Australia; jill.cook@deakin.edu.au

Accepted 18 August 2008
Published Online First
23 September 2008

ABSTRACT

Overuse tendinopathy is problematic to manage clinically. People of different ages with tendons under diverse loads present with varying degrees of pain, irritability, and capacity to function. Recovery is similarly variable; some tendons recover with simple interventions, some remain resistant to all treatments.

The pathology of tendinopathy has been described as degenerative or failed healing. Neither of these descriptions fully explains the heterogeneity of presentation. This review proposes, and provides evidence for, a continuum of pathology. This model of pathology allows rational placement of treatments along the continuum.

A new model of tendinopathy and thoughtful treatment implementation may improve outcomes for those with tendinopathy. This model is presented for evaluation by clinicians and researchers.

Overuse tendon injury (tendinopathy) occurs in loaded tendons of the upper and lower limb and results in pain, decreased exercise tolerance of the tendon and a reduction in function. Characteristic changes occur in tendon structure, resulting in a tendon that is less capable of sustaining repeated tensile load.

Tendon injury can occur in the mid-tendon, as in the Achilles tendon; however, most tendon pathology and pain arise at the tendon attachment to bone, such as the patellar tendon, medial and lateral elbow tendon and tendons of the groin. While the mid-tendon and the insertion are morphologically different in the normal state, the onset of pathology induces cell matrix changes that are indistinguishable; that is, the pathology appears to be the same.¹ Despite a similar pathology, it has been shown in the Achilles that exercise specific for insertional or mid-tendon tendinopathy provides improved clinical outcomes, probably a reflection of the loading profiles in different parts of the tendon.^{2,3}

Load has been shown to be both anabolic and catabolic for tendons.⁴ Repetitive energy storage and release and excessive compression appear to be key factors in the onset of tendinopathy. The amount of load (volume, intensity, frequency) that induces pathology is not clear; however, sufficient time between loadings to allow a tendon to respond to load appears important. Therefore volume (hours) and frequency (sessions per day or week) of intense load may be critical in the capacity of both normal and pathological tendons to tolerate load.⁵ Although load is a major patho-aetiological component, it is almost certainly

modulated by an interaction between intrinsic factors such as genes, age, circulating and local cytokine production, sex, biomechanics and body composition.

Although loading history and individual factors may influence the onset and amount of tendon pathology, these are not generally considered when developing a treatment plan for painful tendons. Treatment for a first-time presentation of tendinopathy in a young athlete is often the same as that offered to a postmenopausal woman with chronic tendinopathy. The model proposed in this paper hypothesises that the pathology and the response to treatment are different in these presentations, and that interventions should be tailored to the pathology. Applying a single intervention to all presentations of tendinopathy is unlikely to be efficacious in every case.

This paper will examine existing concepts of tendinopathy and then present a model for the pathological process in tendon that collates existing knowledge. The model will be based on evidence from clinical and basic science studies in humans to demonstrate its validity.

EXISTING TENDON PATHOLOGY CONCEPTS

At least three states of tendon pathology have been described to date. Following the demise of a primary inflammatory model, tendinopathy was considered to be degenerative. Degenerative tendinopathy is described variably; pathological terms such as hypoxic degeneration, hyaline degeneration and mucoid degeneration are used, all of which suggest non-reparative, end-stage pathology.⁶ The key features of degenerative pathology centre on irreversible, degenerative cell changes and disintegration of the matrix.

Other authors have suggested that injured tendon is in a healing phase, with active cells and increased protein production, but with disorganisation of the matrix and neovascularisation. This has been called failed healing⁷ or angiofibroblastic hyperplasia.⁸

Failed healing and degeneration have been associated with chronic overload, but pathology has also been described when a tendon is unloaded (stress-shielded). Unloading a tendon induces cell and matrix change similar to that seen in an overloaded state⁹ and decreases the mechanical integrity of the tendon.¹⁰ In animals, this state has been shown to be mostly reversible¹¹; however, few human studies have been conducted and tendon unloading will not be considered further in this paper.

Despite these varied descriptions of tendon pathology, the possibility that these may be linked in a continuum has received limited consideration.¹² If a model of pathology can be developed that is continually evaluated and modified in the light of research findings, a better understanding of tendon pathology, treatment and prevention is possible.

A NEW MODEL OF TENDON PATHOLOGY

We propose that there is a continuum of tendon pathology that has three stages: reactive tendinopathy, tendon dysrepair (failed healing) and degenerative tendinopathy (fig 1). The model is described for convenience in three distinct stages; however, as it is a continuum, there is continuity between stages.

Adding or removing load is the primary stimulus that drives the tendon forward or back along the continuum, especially in the early stages. Within the constraints of recovery proposed in the model, reducing load may allow the tendon to return to a previous level of structure and capacity within the continuum.¹³

What are the pathological, imaging and clinical manifestations at each stage?

1. Reactive tendinopathy

It is proposed that reactive tendinopathy, a non-inflammatory proliferative response in the cell and matrix, occurs with acute tensile or compressive overload. This results in a short-term adaptive and relatively homogeneous thickening of a portion of the tendon that will either reduce stress (force/unit area) by increasing cross-sectional area or allow adaptation to compression. This differs from normal tendon adaptation to tensile load, which generally occurs through tendon stiffening with little change in thickness.¹⁴

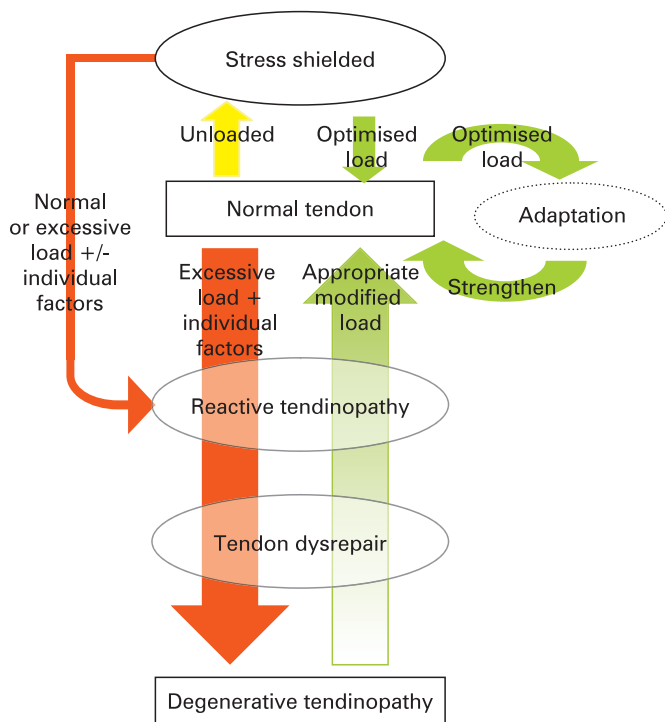


Figure 1 Pathology continuum; this model embraces the transition from normal through to degenerative tendinopathy and highlights the potential for reversibility early in the continuum. Reversibility of pathology is unlikely in the degenerative stage.

Clinically, reactive tendinopathy results from acute overload, usually a burst of unaccustomed physical activity. Reactive tendinopathy can also be seen clearly after a direct blow such as falling directly onto the patellar tendon.¹⁵ This non-tensile, and only transiently compressive, load induces considerable reaction within the tendon cell and matrix.

Evidence that reactive tendinopathy occurs in response to overload is fairly strong from in-vitro work.¹⁶ There is a homogeneous, non-inflammatory cell response to load that leads to metaplastic change in the cells and cell proliferation. Tendon cells become more chondroid in shape, with more cytoplasmic organelles for increased protein production. The primary proteins are large proteoglycans, and this results in matrix change due to an increase in bound water associated with these proteoglycans. Collagen integrity is mostly maintained, although there can be some longitudinal separation, and there is no change in neurovascular structures.

These initial changes in ground substance in reactive tendinopathy may occur because quick adaptation is necessary until longer-term change in either structure or mechanical properties (true adaptation) happens. The quick response is possible as larger proteoglycans associated with tendinopathy (aggrecan and versican) and some glycoproteins (hyaluronan) can be upregulated in a timespan varying from minutes to a few days, much more quickly than the small proteoglycans of normal tendon (20 days).¹⁷

Thus, reactive response is a short-term adaptation to overload that thickens the tendon, reduces stress and increases stiffness. The tendon has the potential to revert to normal if the overload is sufficiently reduced or if there is sufficient time between loading sessions.

Imaging

The tendon is swollen in a fusiform manner; the diameter is increased on both magnetic resonance imaging (MRI) and ultrasound (US) scans. Ultrasound shows reflection from intact collagen fascicles, with diffuse hypoechogenicity occurring between intact collagen structures. Magnetic resonance imaging will show minimal or no increased signal at this stage. The change in imaging appearance is mainly derived from the increase in bound water within the proteoglycans (fig 2).

Clinical

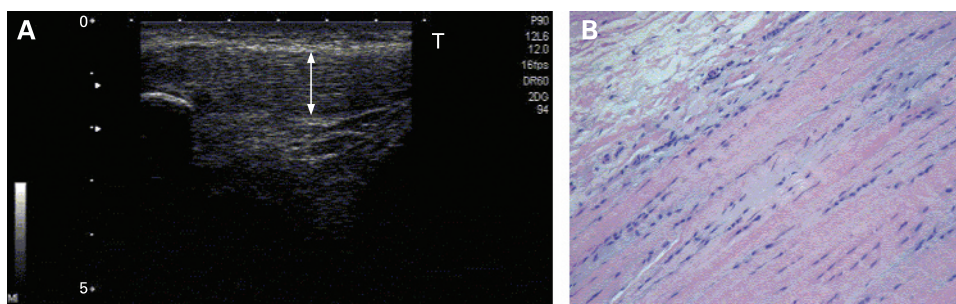
Reactive tendinopathy is seen clinically in an acutely overloaded tendon and is more common in a younger person. For example, a young jumping athlete who dramatically increases the number of jumping/landing repetitions a week may develop patellar tendon swelling and pain.

Tendons chronically exposed to low levels of load (e.g. in the detrained athlete returning from illness or injury, or a sedentary person) may also be vulnerable to this stage of tendinopathy when exposed to moderate increase in load. In addition it may occur as a result of direct trauma to tendon, to which the Achilles, patellar and elbow tendons are particularly exposed.

2. Tendon dysrepair

Tendon dysrepair describes the attempt at tendon healing, similar to reactive tendinopathy but with greater matrix breakdown. There is an overall increase in number of cells, which are mainly chondrocytic, as well as some myofibroblasts, resulting in a marked increase in protein production (proteoglycan and collagen). The increase in proteoglycans results in separation of the collagen and disorganisation of the matrix.

Figure 2 (A) Ultrasound image of a thickened patellar tendon with intact collagen fascicles. The arrow indicates the width of the tendon. (B) Histopathological appearance of reactive tendinopathy/early tendon dysrepair. Note the increased cell numbers and intermittent cell rounding with some evidence of increased ground substance (light blue shading) (histology picture by courtesy of F Bonar).



The changes are somewhat more focal and matrix changes more varied than in the reactive stage. There may be an increase in vascularity and associated neuronal ingrowth.¹⁸

Imaging

The imaging changes reflect increased matrix disorganisation, and these tendons are swollen, with increasing evidence of collagen disorganisation. On US there is some discontinuity of collagen fascicle and small focal areas of hypoechogenicity. The increase in vascularity may be evident on colour or power Doppler, and techniques to enhance vascularity (heat, exercise, hanging the limb) (personal communication, Cormick, 2008) may show a greater number of vessels. On MRI the tendon is swollen and there is increased signal within the tendon.

Clinical

This pathology has been reported in chronically overloaded tendons in the young,¹⁹ but may appear across a spectrum of ages and loading environments. This stage may be hard to distinguish clinically; these tendons are thick with more localised changes in one area of the tendon. Tendon dysrepair is best detected when imaging detects some focal structural changes with or without increased vascularity.

The frequency, volume or length of time over which load has been applied (ie, months or years of overload) may be important variables. An older person with stiffer tendons that have less adaptive ability may develop this stage of tendinopathy with relatively lower loads. Some reversibility of the pathology is still possible with load management and exercise to stimulate matrix structure.²⁰

3. Degenerative tendinopathy

This stage is clearly described in the literature, with progression of both matrix and cell changes.⁸ Areas of cell death due to apoptosis, trauma or tenocyte exhaustion are apparent.²¹ As a result, areas of acellularity have been described, and large areas of the matrix are disordered and filled with vessels, matrix breakdown products and little collagen. There is little capacity for reversibility of pathological changes at this stage. There is considerable heterogeneity of the matrix in these tendons, with islands of degenerative pathology interspersed between other stages of pathology and normal tendon.

Imaging

The compromised matrix and the vascular changes can be extensive. These appear on ultrasound scans as hypoechoic regions with few reflections from collagen fascicles. Numerous and larger vessels are usually visible on Doppler US. Magnetic resonance imaging demonstrates increased tendon size and

intratendinous signal. The changes are more focal rather than spread throughout the tendon.

Clinical

This stage is primarily seen in the older person, but is seen in a younger person or elite athlete with a chronically overloaded tendon. The classic presentation is a middle-aged, recreational athlete with focal Achilles tendon swelling and pain. The tendon can have one or more focal nodular areas with or without general thickening. Individuals with degenerative changes often have a history of repeated bouts of tendon pain, often resolving but returning as the tendon load changes. Degenerative tendinopathy, if extensive enough, or if the tendon is placed under high load, can rupture,²² consistent with 97% of tendons that rupture having degenerative change.²³

EVIDENCE TO SUPPORT THIS MODEL

As longitudinal monitoring of histopathological change in humans is ethically difficult, the stages and progressions suggested in this model have been derived from integrating evidence from cross-sectional studies and supported by findings in animal models. Limited weight has been placed on outcomes in animal studies, as animal tendons do not directly translate to human tendinopathy. Longitudinal imaging studies in humans allow tracking of tendon change over time, and these demonstrate that some transition up and down the proposed pathology model occurs. Finally, limited evidence is available from clinical studies.

The concepts embedded in this model are strikingly similar to those reported for articular cartilage pathology.²⁴ In osteoarthritis Pollard *et al* proposed a continuum from a reversible stage through to advanced osteoarthritis (table 1). The initial response centred on reversible proteoglycan upregulation, initial swelling and cellular upregulation, through to the latter stages of irreversible heterogeneous tissue change including cell and cartilage degeneration and erosion and subchondral bone remodelling.

Histopathological studies

Evaluation of human asymptomatic tendons demonstrated that cell change was always present when matrix change became apparent.²⁵ Additionally, matrix change was primarily in ground substance, followed by collagen, and then (theoretically but not demonstrated) in vascularity. This provides evidence for the progression from normal to reactive response and tendon dysrepair; however, this study did not examine tendons that would be classified as degenerative. Although not considered a good model for human overuse tendinopathy, animal studies support these findings. Scott *et al*¹⁶ reported similar progression in pathology in overloaded rat supraspinatus tendons.

Table 1 Stages of osteoarthritis

Feature	Reversible injury	Osteoarthritis	Ageing
Cartilage mass	Hypertrophy	Hypertrophy, erosion	No Change
Cartilage topographic distribution	Focal	Focal. Heterogeneous	General, all layers
Cartilage water	Oedema	Oedema	Dehydration
Cartilage collagen	Reversible deformation	Degradation	Increased advanced glycation end products
Cartilage proteoglycan	Reversible depletion	Irreversible depletion	Reduced synthesis
Cartilage matrix degeneration products	Resorption	Accumulative, collagen, proteoglycan	Accumulative: oxidation. Glycation, amyloid
Cell activity	Reversibly increased	Increased activity and proliferation	Reduced
Synovium	Mid focal superficial inflammation	Mid focal superficial inflammation	Atrophy
Bone	No Change	Subchondral remodelling	Osteopenia

Reproduced with permission and copyright© of the British Editorial Society of Bone and Joint Surgery. Pollard *et al*, 2008. The assessment of early osteoarthritis. *J Bone Joint Surg Br*;90-B:411–21.

Degenerative tendinopathy has been extensively described, but the transition from dysrepair has not been demonstrated.

Imaging studies

Acute tendon response

An acute bout of exercise increased the MRI volume and signal in abnormal Achilles tendon.²⁶ This suggests several critical things: tendon response is rapid, and tendon response is to increase volume (circumference) and water (either bound as part of ground substance or in vessels). This is the earliest form of the reactive response to load proposed in this model.

Normal to reactive, and back

Several studies demonstrate both short-term and long-term changes in the imaging appearance of tendons. Nearly half of normal patellar tendons (with pain) became abnormal (mainly reactive tendinopathy) in the presence of ongoing load over a season of volleyball (high tendon load). A single tendon became hypoechoic, suggesting transition through a reactive tendinopathy to tendon dysrepair/degenerative tendinopathy.²⁷

Longitudinal imaging studies have consistently demonstrated that between 10% and 30% of tendons reported as abnormal at baseline become normal at follow-up.^{28–30} This supports the viability of a transition from reactive change back to normal tendon.

Reactive to dysrepair

In a group of young athletes at risk of tendon overload and pathology there was a subgroup with microhypoechoic areas on US.¹⁹ This may represent a transition from reactive to tendon dysrepair, where small islands of the tendon develop collagen disorganisation. There is little evidence of reversal of this transition in the longitudinal studies to date.

Dysrepair to degenerative tendinopathy

This transition is not clearly demonstrated in the literature, as they are both considered abnormal and are not often identified as separate entities. Imaging evaluation of highly loaded patellar

tendons in jumping athletes demonstrate that they primarily transition towards abnormality and pain that is more apparent in adults³¹ than in adolescents.³²

Clinical studies

The cumulative effect of load on a tendon has been clearly demonstrated when the tendon health of athletes who placed high loads on their Achilles tendons in early adulthood was later evaluated. Previous elite athletes had a higher cumulative incidence of tendinopathy and rupture than age-matched controls.³³ As rupture represents end-stage degenerative tendinopathy,²³ the higher rupture rates support high chronic load as an important factor in tendon pathology. This also supports the non-reversible nature of degenerative pathology, as these older ex-athletes had not spontaneously recovered tendon health.

The inability of a tendon to recover once it reaches the degenerative stage is supported by studies that have examined tendons many years after injury or rupture. Although the tendons may improve their function, they do not appear to return to normal size or morphology. Several studies have shown that large hypoechoic areas do not change,^{34–36} and similarly tendons used for anterior cruciate ligament graft replacements remain abnormal for years.³⁷

PLACING CLINICAL TREATMENTS IN THE PATHOLOGY MODEL

Deciding where a tendon is in the pathological spectrum

For ease of use clinically, we have divided the pathology into two clear groups: reactive/early tendon dysrepair and late tendon dysrepair/degenerative. This will allow most clinical tendon presentations to be clearly placed in one of the two categories based on clinical assessment.

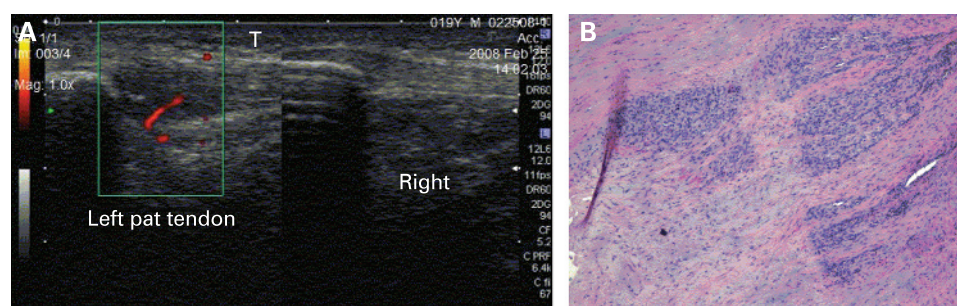
Clinical and imaging features allow a tendon to be placed in one of these two categories. An older person with a thick nodular tendon is likely to have a degenerative tendon; conversely, a young athlete after acute overload with a fusiform swelling of the tendon will probably have a reactive tendinopathy. There are, however, tendons in which it may be clinically difficult to stage the pathology, and in these tendons imaging may give vital clues. If the tendon is generally swollen and mildly hypoechoic or has small focal hypoechoic areas (one or several) with no or minimal vascular changes, this indicates reactive/early tendon dysrepair (fig 2). Tendons with large discrete areas of hypoechoicogenicity, multiple vessels and more focal swelling will be in the late tendon dysrepair/degenerative category (fig 3).

This division of a continuum into two categories allows us to have a nominal threshold beyond which tendons will not fully return to normal structure. Cell dysfunction or death that compromises matrix protein production and/or the inability of the matrix to regain structural integrity results in a tendon incapable of full repair. It has been demonstrated that even after improvement in Achilles tendon pain and tendon structure and vascularity after an eccentric exercise programme, the tendon remains thicker than normal for several years.²⁰

PLACING PAIN IN THIS MODEL OF TENDINOPATHY

Pain can occur at any point in this pathological model, supporting the well-known dissociation between pain and pathology in tendinopathy. Even tendons that appear normal on imaging can be painful.²⁷ Conversely, two-thirds of tendons degenerative enough to rupture have been reported to be pain-free before rupture.²³

Figure 3 (A) Ultrasound of a normal right and tendon dysrepair/degenerative left patellar tendon. Note the vessel evident on power Doppler in the left tendon, the hypoechoic area and the tendon swelling. (B) Histopathological appearance of late tendon dysrepair/degeneration. Note the markedly increased cell numbers, the loss of collagen evidenced by the loss of longitudinal rows of cells, and the increase in vessels (histology picture by courtesy of F Bonar).



The source of pain has been associated with neurovascular ingrowth,³⁸ seen in this model at the late tendon dysrepair/degenerative phase. However, the fact that tendons can be painful or pain-free anywhere in this model suggests another or supplementary cause of pain that has so far proved elusive. The presence of biochemical substances stimulated by overload (compression or tension) and/or acting on sensitised nerves in matrix seems to be one possibility. Cell production of substances such as catecholamines, acetylcholine and glutamate acting on their receptors, which allow autocrine/paracrine signalling, has been described,³⁹ which may explain pain in the cellularly active stages in this model: reactive and tendon dysrepair.

Pain is the single clinical feature that the clinician seeks to change, and pain response to treatment is a key indicator of treatment success. If pain levels and response to load are considered with the stage of pathology, treatment progression and outcomes may improve.

Tendinopathic pain is induced by load and has two key features: (1) dose-dependent pain in relation to singular or cumulative load, and (2) pain that is well localised to the tendon or enthesis. Increasing load on the tendon will usually increase pain. During assessment, the tendon should be provocatively loaded to functional levels to fully evaluate the level of pain.

Pain should be assessed in the context of the stage and level of pathology; an extensively degenerated tendon with mild pain can have insufficient integrity to tolerate high loads and has a risk of rupture. Conversely, a proliferative tendinopathy is more reactive and therefore assessment needs to be more conservative when loading during assessment.

TREATMENT OF TENDINOPATHY

Clinical treatments directed at effecting change in tendon structure or pathology are considered optimal interventions, but, as pain is often the clinical presentation, a case can be made for concentrating on reduction of pain as a valid outcome. It is evident that pain can occur anywhere in the pathological continuum; interventions that reduce pain and are also appropriate for the stage of pathology should, therefore, be our ideal. Conversely, inappropriate treatments for the stage of pathology (such as “loading up” of a tendon in the proliferative phase of tendinopathy) may increase pain, leading to a poor clinical outcome.⁴⁰ Common interventions and their proposed place in this model are summarised in table 2. In an effort to maintain clarity of approach, polymodal interventions, often undertaken in the clinical management of tendinopathy, have not been considered.

Reactive tendinopathy/early tendon dysrepair

Physical treatments

At this stage load management (reduction) will generally allow the tendon time to adapt, the cells to become less reactive and

the matrix to resume a more normal structure. Also, a tendon with reduced load is likely to have less pain. Identifying and changing the abusive load may be as simple as allowing a day or two between high or very high tendon loads. Assessment and modification of the intensity, duration, frequency and type of load is the key clinical intervention. This may include identifying the potential for biomechanical overload. Studies show that tendon response in type 1 collagen precursors peaks around 3 days after a single bout of intense exercise, suggesting that time interval for adaptive response is an important factor.⁴¹ Tendon load without energy storage and release, such as cycling or strength-based weight training, can be maintained, as this is less likely to induce further tendon response. Conversely, high-load elastic or eccentric loading, particularly with little recovery time (eg, on successive days), will tend to aggravate tendons in this stage.

Pharmacotherapies

Non-steroidal anti-inflammatory medications (NSAIDs) have been reported to retard soft tissue healing in a range of tissues. Although pain may be reduced, they have a negative effect on tendon repair.⁴² In reactive tendinopathy, this may be a preferred effect, as tenocyte upregulation and excess ground substance expression are apparent in this phase of tendinopathy.²⁵ Ibuprofen (as well as indomethacin and naproxen sodium) has been shown to inhibit expression of key ground substance proteins responsible for tendon swelling (aggrecan) in in-vitro tendon preparations.⁴³ Ibuprofen and celecoxib are also reported to have a specific effect in downregulating the cellular response.^{44 45} Ibuprofen may be favoured as it has not been shown to have a detrimental effect on ultimate tendon repair.⁴²

Corticosteroids, primarily used to decrease pain, also decrease cell proliferation and protein production and therefore could be used in the reactive painful tendon. Repeated peritendinous corticosteroid has been shown to reduce tendon diameter at 7 and 21 days after injection in tendons.⁴⁶ Although peritendinous injection is clinically accepted, it is not known whether peritendon injection induces cell and matrix change within the tendon.

Late tendon dysrepair/degenerative tendinopathy

Physical treatments

Treatments that stimulate cell activity, increase protein production (collagen or ground substance) and restructure the matrix are appropriate for this stage of tendinopathy. Exercise interventions are discussed separately below.

Frictions have been proposed as an effective treatment in tendon injury, and the rationale for their use, based on improving tendon structure, fits into this stage of tendon pathology. They have been shown to increase protein production in animals,⁴⁷ but

Table 2 Clinical and pharmacological treatments placed in the model

Stage	Pharmacological management	Physical management
Reactive tendinopathy/early tendon dysrepair	Tenocyte inhibitors (ibuprofen, celecoxib, corticosteroid), aggrecan inhibitors (ibuprofen, naproxen sodium, indomethacin)	Load management. Reduction in frequency \pm intensity of tendon load
Late tendon dysrepair/degeneration	Prolotherapy (including blood), aprotinin, sclerosing therapy, glyceryl trinitrate	Exercise with eccentric component, ESWT, frictions, ultrasound

ESWT, extracorporeal shock wave therapy.

in humans few stringent investigations have been conducted,⁴⁸ and the results are variable. Clinically, compared with exercise, frictions were less effective in reducing pain.⁴⁹

Extracorporeal shock wave therapy (ESWT) has been shown to have pain-relieving effects in a number of tendons, although ESWT is not consistently shown to be superior to placebo treatment. Studies in animal tendons show variable morphological and mechanical benefits and detriments from this modality, but it may be of benefit in this stage of pathology.⁵⁰

Ultrasound has been shown to increase protein production at a tissue level.⁵¹ Similarly to frictions, it is less effective than exercise in treating patellar tendinopathy.^{49 52}

Surgery for chronic painful (presumably degenerative) tendons has produced varied outcomes, with 50–80% of athletes able to return to sport at their previous level.^{53–55} Although surgical techniques vary considerably, their results are not dissimilar.⁵⁶ Outcome after surgery was no better than eccentric exercise⁵⁷ or ESWT⁵⁸ for patellar tendinopathy. Surgery in non-athletic people produced poorer results than in active people.⁵⁹ Despite these outcomes, surgery is considered a reasonable option in those who have failed conservative interventions.

Pharmacotherapies

Treatments that stimulate a healing response in the tendon are appropriate for degenerative tendinopathy. The injection of various substances around or into the tendon or the process of injection itself has been proposed to achieve this.

Prolotherapy using glucose and blood injections stimulates a tissue response. Blood injection stimulates cell proliferation and production of vascular endothelial growth factor,⁶⁰ and it has been demonstrated to induce matrix changes. Clinically, blood injections have led to reduced vascularity and decreased tendon diameter on ultrasound.⁶¹

Injection itself, regardless of the substances injected, has been shown to have a beneficial effect on tendon structure. Multiple tendon biopsies improved structural outcome in degenerative tendons at 1 year compared with an untreated group,⁶² and injections of active (polidocinol) and placebo (anaesthetic and adrenaline) substances produced similar outcome.⁶³

Aprotinin, a collagenase inhibitor, may preserve collagen in a remodelling matrix. A recent randomised placebo-controlled trial did not show benefits of aprotinin over placebo,⁶⁴ although earlier studies have shown an effect on pain.⁶⁵

Sclerosing therapy has repeatedly been shown to be effective in treating pain and improving structure in tendinopathy.⁶⁶ When compared with placebo, both pain and structural outcomes were significantly better with the sclerosing treatment in both Achilles and patellar tendon.⁶⁷ Interestingly, the effect on vessels appears to be delayed, with vascularity increasing in the short term after treatment, suggesting that the positive effect on pain may be through chemical neurolysis rather than vascular change.⁶⁸

Glyceryl trinitrate has been shown to effectively reduce tendon pain in addition to the benefits of eccentric exercise.^{69–71} It is reported to deliver increased amounts of nitric oxide to the injured tendon, leading to improvement in collagen synthesis, although a recent study has not demonstrated increased tissue levels of NO or benefit from the treatment.⁷² These studies have not examined the long-term effect of this treatment on tendon structure or tendon vascularity.

PLACING EXERCISE IN THIS MODEL

Exercise, particularly eccentric exercise, has been shown to affect both tendon structure and pain. Eccentric exercise has been shown to increase collagen production in abnormal tendons but not in normal tendons.⁷³ Eccentric exercise has been shown to improve tendon structure in both the short term⁷⁴ and the longer term²⁰ and decrease tendon vessels.⁷⁵ Eccentric exercise is an effective pain-relieving treatment, with pain changing in the first 4–6 weeks.⁷⁶ A meta-analysis reported that eccentric exercise is beneficial for pain, function and return to activity.⁷⁷

In this model, for athletes in an earlier stage of tendinopathy, who are already loading the tendon in a significant manner, adding exercise (painful or not) may not improve outcome.^{41 78} This model hypothesises that exercise is a potent stimulus to the already upregulated tendon cells and overstimulates a fundamentally intact, but reactive (or sensitised), matrix. In degenerative tendinopathy, exercise appears to be a positive stimulus for cell activity and matrix restructuring.

In degenerative tendons, exercise-based treatments allow variable levels of pain. The Alfredson eccentric exercise programme suggests that pain during exercise in this stage may be tolerated by the tendon.⁷⁹ This is supported by Silbernagel *et al*, whose study in a similar population allowed activity pain of less than 5/10 during activity.⁸⁰ There was no difference in outcome when compared with a group that just exercised without continuing activity. These studies suggest that exercise that induces pain in the degenerative stage will not affect outcome. If pain in degenerative tendinopathy is mediated by neurovascular structures more than cellular products, as this model suggests, then neurovascular pain appears to be less reactive and tendons would be less irritable in this stage of tendinopathy.

DISCUSSION

We present a simple and succinct model of tendon pathology, which is consistent with the clinical presentations of tendinopathy. The aim of this model is to logically order treatment options for clinicians. Although we have used the term load-induced tendinopathy, we have deliberately not detailed what type of load is responsible. Debate on the relative contribution of tensile, compressive and combined loads is for other fora.

Although these are presented as discrete stages of pathology, it is highly probable that some tendons may have discrete regions that are in different stages at the one time. Examination of tissue, particularly in the latter stages of pathology, often reveals heterogeneous pathology in a single tendon.⁸¹ It is possible that a tendon with degenerative change that is acutely overloaded may develop reactive change in previously normal parts of the tendon. Evaluating these more complex presentations has deliberately not been discussed in this paper to maintain simplicity. Improving capacity to clinically evaluate and treat these more difficult tendons is primarily dependent on accepting the basic model presented.

Research into tendinopathy may also be improved by considering this model. It is possible that the variable response to tendon treatment in research studies may be explained to some extent through the existence of subpopulations of different pathologies in the investigated cohort. In fact, the most consistent outcomes in research appear to occur when the participants are clearly in one group, such as in Alfredson's eccentric exercise research on older, presurgical patients.

Very little research has been conducted in early-stage tendinopathy, possibly because of the inherent capacity of these tendons to spontaneously recover, the variability of pain presentation and the difficulties in assembling a sizeable cohort.

The individual factors considered earlier (genes, age, circulating and local cytokine production, sex, biomechanics and body composition) may alter the progression forward or back in the continuum⁶² and most are also likely to have an important role in the response to treatment in tendinopathy. For example, some athletes appear completely resistant to tendinopathy despite high loads, and have never been shown to progress into proliferative tendinopathy. Conversely, other athletes sustain tendon ruptures relatively early in their careers, presumably after some degenerative change in the tendon. Identifying athletes at risk of tendon pathology, as well as using this model in treatment, may improve outcomes. Early load management in at-risk athletes may keep them in the early stages of tendon pathology and limit progression.

Time to recovery should be inherent in a clinical model such as this; however, the capacity for tendons to transition up and down between stages makes time estimates for recovery difficult. Overall, tendons respond very slowly, both in improving load capacity and in resolving pain.

CONCLUSIONS

This model explains most clinical presentations and most findings in the tendon literature. It can even encompass primary collagen tearing⁶³ and some form of inflammation underpinning the cell and matrix response. Emerging mechanisms for injury, complex interactions between the cell and matrix and systemic and local factors (growth factors, cytokines and treatments) will need to be built into this model. The integrity of the model will only be as good as its capacity to withstand additional research. This model now requires scientific and clinical evaluation.

Funding: Jill Cook was funded by a Club Warehouse Visiting Fellowship to the Australian Institute of Sport Physical Therapies department. Club Warehouse had no direct or indirect involvement in the production of this manuscript.

Competing interests: None declared.

REFERENCES

- Maffulli N, Testa V, Capasso G, et al. Similar histopathological picture in males with Achilles and patellar tendinopathy. *Med Sci Sport Exerc* 2004;**36**:1470–5.
- Fahlstrom M, Jonsson P, Lorentzon R, et al. Chronic Achilles tendon pain treated with eccentric calf-muscle training. *Knee Surg Sports Traumatol Arthrosc* 2003;**11**:327–33.
- Jonsson P, Cook J, Alfredson H. New regimen for eccentric calf muscle training in patients with chronic insertional Achilles tendinopathy: Results of a pilot-study. *Br J Sports Med* 2008;**42**:746–9.
- Benjamin M. Tendons are dynamic structures that respond to changes in exercise levels. *Scand J Med Sci Sports* 2002;**12**:63–4.
- Langberg H, Skovgaard D, Asp S, et al. Time pattern of exercise-induced changes in Type I collagen turnover after prolonged endurance exercise in humans. *Calcif Tissue Int* 2000;**67**:41–4.
- Jozsa L, Kannus P. Histopathological findings in spontaneous tendon ruptures. *Scand J Med Sci Sports* 1997;**7**:113–18.
- Clancy W. Failed healing responses. In: W Leadbetter, J Buckwater, S Gordon, eds. *Sports-Induced Inflammation: clinical and basic science concepts*. Park Ridge, IL: American Orthopedic Society for Sports Medicine, 1989.
- Kraushaar B, Nirschl R. Tendinosis of the elbow (tennis elbow). Clinical features and findings of histological, immunohistochemical, and electron microscopy studies. *J Bone Joint Surg Am* 1999;**81-A**:259–78.
- Ohno K, Yasuda K, Yamamoto N, et al. Effects of complete stress-shielding on the mechanical properties and histology of in situ frozen patellar tendon. *J Orthop Res* 1993;**11**:592–602.
- Kubo K, Akima H, Ushiyama J, et al. Effects of 20 days of bed rest on the viscoelastic properties of tendon structures in lower limb muscles. *Br J Sports Med* 2004;**38**:324–30.
- Yamamoto N, Hayashi K, Kuriyama H, et al. Effects of restressing on the mechanical properties of stress-shielded patellar tendons in rabbits. *J Biomech Eng* 1996;**118**:216–20.
- Neer CS. Impingement lesions. *Clin Orthop Related Res* 1983;**173**:70–7.
- Cook JL, Khan KM, Kiss ZS, et al. Asymptomatic hypoechoic regions on patellar tendon ultrasound: A 4-year clinical and ultrasound followup of 46 tendons. *Scand J Med Sci Sports* 2001;**11**:321–7.
- Magnusson SP, Narici MV, Maganaris CN, et al. Human tendon behaviour and adaptation, in vivo. *J Physiol* 2008;**586**:71–81.
- Garau G, Rittweger J, Malliaras P, et al. Traumatic patellar tendinopathy. *Disability and Rheumatism* 2008;**30**:1616–20.
- Scott A, Cook JL, Hart DA, et al. Tenocyte responses to mechanical loading in vivo: A role for local IGF-I signaling in early tendinosis. *Arthritis and Rheumatism*. In press.
- Samiric T, Ilic MZ, Handley CJ. Characterisation of proteoglycans and their catabolic products in tendon and explant cultures of tendon. *Matrix Biol* 2004;**23**:127–40.
- Danielson P, Alfredson HK, Forsgren S. Distribution of general (PGP 9.5) and sensory (substance P/CGRP) innervations in the human patellar tendon. *Knee Surg Sports Traumatol Arthrosc* 2006;**14**:125–32.
- Cook JL, Khan KM, Kiss ZS, et al. Patellar tendinopathy in junior basketball players: A controlled clinical and ultrasonographic study of 268 patellar tendons in players aged 14–18 years. *Scand J Med Sci Sports* 2000;**10**:216–20.
- Ohberg L, Lorentzon R, Alfredson H. Eccentric training in patients with chronic Achilles tendinosis: normalised tendon structure and decreased thickness at follow up. *Br J Sports Med* 2004;**38**:8–11.
- Lian O, Scott A, Engebretsen L, et al. Excessive apoptosis in patellar tendinopathy in athletes. *Am J Sports Med* 2007;**35**:605–11.
- Nehrer R, Breitenseher M, Brodner W, et al. Clinical and sonographic evaluation of the risk of rupture in the Achilles tendon. *Arch Orthop Trauma Surg* 1997;**116**:14–18.
- Kannus P, Jozsa L. Histopathological changes preceding spontaneous rupture of a tendon. A controlled study of 891 patients. *J Bone Joint Surg Am* 1991;**73**:1507–25.
- Pollard T, Gwilym S, Carr A. The assessment of early osteoarthritis. *J Bone Joint Surg Br* 2008;**90-B**:411–21.
- Cook JL, Feller JA, Bonar SF, et al. Abnormal tenocyte morphology is more prevalent than collagen disruption in asymptomatic athletes' patellar tendons. *J Orthop Res* 2004;**22**:334–8.
- Shalabi A, Kristoffersen-Wiberg M, Aspelin P, et al. Immediate Achilles tendon response after strength training evaluated by MRI. *Med Sci Sport Exerc* 2004;**36**:1841–6.
- Malliaras P, Cook J. Patellar tendons with normal imaging and pain: Change in imaging and pain status over a volleyball season. *Clin J Sports Med* 2006;**16**:388–91.
- Cook J, Kiss Z, Khan K, et al. Prospective imaging study of asymptomatic patellar tendinopathy in elite junior basketball players. *J Ultrasound Med* 2000;**19**:473–9.
- Fredberg U, Bolvig L. Significance of ultrasonographically detected asymptomatic tendinosis in the patellar and achilles tendons of elite soccer players: a longitudinal study. *Am J Sports Med* 2002;**30**:488–91.
- Khan KM, Cook JL, Kiss ZS, et al. Patellar tendon ultrasonography and jumper's knee in female basketball players: A longitudinal study. *Clin J Sport Med* 1997;**7**:199–206.
- Malliaras P, Cook J. Prospective study of change in patellar tendon abnormality on imaging and pain over a volleyball season. *Br J Sports Med* 2005;**40**:272–4.
- Gisslen K, Alfredson H. Neovascularisation and pain in jumper's knee: a prospective clinical and sonographic study in elite junior volleyball players. *Br J Sports Med* 2005;**39**:423–8; discussion 423–8.
- Kujala UM, Sarna S, Kaprio J. Cumulative incidence of achilles tendon rupture and tendinopathy in male former elite athletes. *Clin J Sport Med* 2005;**15**:133–5.
- Adriani E, Mariani PP, Maresca G, et al. Healing of the patellar tendon after harvesting of its mid-third for anterior cruciate ligament reconstruction and evolution of the unclosed donor site defect. *Knee Surg Sports Traumatol Arthrosc* 1995;**3**:138–43.
- Karjalainen PT, Aronen HJ, Pihlajamaki HK, et al. Magnetic resonance imaging during healing of surgically repaired Achilles tendon ruptures. *Am J Sports Med* 1997;**25**:164–71.
- Sanchez-Alfonso V, Subias-Lopez A, Monteagudo-Castro C, et al. Healing of the patellar tendon donor defect created after central-third patellar tendon autograft harvest. *Knee Surg Sports Traumatol Arthrosc* 1999;**7**:340–8.
- Kiss ZS, Kellaway DP, Cook JL, et al. Postoperative patellar tendon healing: An ultrasound study. VIS Tendon Study Group. *Australas Radiol* 1998;**42**:28–32.
- Alfredson H. The chronic painful Achilles and patellar tendon: research on basic biology and treatment. *Scand J Med Sci Sports* 2005;**15**:252–9.
- Danielson P, Alfredson HK, Forsgren S. Immunohistochemical and histochemical findings favoring the occurrence of autocrine/paracrine as well as nerve-related cholinergic effects in chronic painful patellar tendon tendinosis. *Microsc Res Tech* 2006;**69**:808–19.

40. **Fredberg U**, Bolvig L, Andersen NT. Prophylactic training in asymptomatic soccer players with ultrasonographic abnormalities in Achilles and patellar tendons: the Danish Super League Study. *Am J Sports Med* 2008;**36**:451–60.
41. **Langberg H**, Skovgaard D, Petersen LJ, *et al*. Type I collagen synthesis and degradation in peritendinous tissue after exercise determined by microdialysis in humans. *J Physiol* 1999;**521**:299–306.
42. **Ferry ST**, Dahners LE, Afshari HM, *et al*. The effects of common anti-inflammatory drugs on the healing rat patellar tendon. *Am J Sports Med* 2007;**35**:1326–33.
43. **Riley GP**, Cox M, Harrall RL, *et al*. Inhibition of tendon cell proliferation and matrix glycosaminoglycan synthesis by non-steroidal anti-inflammatory drugs in vitro. *J Hand Surg Br* 2001;**26B**:224–8.
44. **Tsai WC**, Tang FT, Hsu CC, *et al*. Ibuprofen inhibition of tendon cell proliferation and upregulation of the cyclin kinase inhibitor p21CIP1. *J Orthop Res* 2004;**22**:586–91.
45. **Tsai WC**, Hsu CC, Chou SW, *et al*. Effects of celecoxib on migration, proliferation and collagen expression of tendon cells. *Connect Tissue Res* 2007;**48**:46–51.
46. **Fredberg U**, Bolvig L, Pfeiffer-Jensen M, *et al*. Ultrasonography as a tool for diagnosis, guidance of local steroid injection and, together with pressure algometry, monitoring of the treatment of athletes with chronic jumper's knee and Achilles tendinitis: a randomized double-blind, placebo-controlled trial. *Scand J Rheumatol* 2004;**33**:94–101.
47. **Gehlsen G**, Ganton L, Helfst R. Fibroblast responses to variation in soft tissue mobilisation pressure. *Med Sci Sport Exerc* 1999;**31**:531–5.
48. **Wilson JK**, Sevier TL, Helfst R, *et al*. Comparison of rehabilitation methods in the treatment of patellar tendinitis. *Journal of Sport Rehabilitation* 2000;**9**:304–14.
49. **Stasinopoulos D**, Stasinopoulos I. Comparison of effects of exercise programme, pulsed ultrasound and transverse friction in the treatment of patellar tendinopathy. *Clin Rehabil* 2004;**18**:347–52.
50. **Maier M**, Milz S, Wirtz DC, *et al*. [Basic research of applying extracorporeal shockwaves on the musculoskeletal system. An assessment of current status]. *Der Orthopade* 2002;**31**:667–77.
51. **Enwemeka CS**. Inflammation, cellularity, and fibrillogenesis in regenerating tendon: implications for tendon rehabilitation. *Phys Ther* 1989;**69**:816–25.
52. **Warden S**. Low-intensity pulsed ultrasound for chronic patellar tendinopathy: a randomised, double-blind, placebo-controlled trial. *Rheumatology*. In press.
53. **Coleman BD**, Khan KM, Kiss ZS, *et al*. Open and arthroscopic patellar tenotomy for chronic patellar tendinopathy. A retrospective outcome study. Victorian Institute of Sport Tendon Study Group. *Am J Sports Med* 2000;**28**:183–90.
54. **Paavola M**, Kannus P, Paakkala T, *et al*. Long-term prognosis of patients with Achilles tendinopathy. An observational 8-year follow-up study. *Am J Sports Med* 2000;**28**:634–42.
55. **Tallon C**, Coleman B, Khan K, *et al*. Outcome of surgery for chronic Achilles tendinopathy. *Am J Sports Med* 2001;**29**:315–20.
56. **Coleman BD**, Khan KM, Kiss ZS, *et al*. Outcomes of open and arthroscopic patellar tenotomy for chronic patellar tendinopathy: a retrospective study. *Am J Sports Med* 2000;**28**:1–8.
57. **Bahr R**, Fossan B, Loken S, *et al*. Surgical treatment compared with eccentric training for patellar tendinopathy (Jumper's Knee). A randomized, controlled trial. *J Bone Joint Surg Am* 2006;**88**:1689–98.
58. **Peers KH**, Lysens RJ, Brys P, *et al*. Cross-sectional outcome analysis of athletes with chronic patellar tendinopathy treated surgically and by extracorporeal shock wave therapy. *Clin J Sport Med* 2003;**13**:79–83.
59. **Maffulli N**, Testa V, Capasso G, *et al*. Surgery for chronic Achilles tendinopathy yields worse results in nonathletic patients. *Clin J Sport Med* 2006;**16**:123–8.
60. **Anitua E**, Andia I, Sanchez M, *et al*. Autologous preparations rich in growth factors promote proliferation and induce VEGF and HGF production by human tendon cells in culture. *J Orthop Res* 2005;**23**:281–6.
61. **Suresh SP**, Ali KE, Jones H, *et al*. Medial epicondylitis: is ultrasound guided autologous blood injection an effective treatment? *Br J Sports Med* 2006;**40**:935–9.
62. **Shalabi A**, Svensson L, Kristoffersen-Wilberg M, *et al*. Tendon injury and repair after core biopsies in chronic Achilles tendinosis evaluated by serial magnetic resonance imaging. *Br J Sports Med* 2004;**38**:606–12.
63. **Zeisig E**, Fahlström M, Öhberg L, *et al*. Pain relief after intratendinous injections in patients with tennis elbow: results of a randomised study. *Br J Sports Med* 2008;**42**:267–71.
64. **Brown R**, Orchard J, Kinchington M, *et al*. Aprotinin in the management of Achilles tendinopathy: a randomised controlled trial. *Br J Sports Med* 2006;**40**:275–9.
65. **Capasso G**, Testa V, Maffulli N, *et al*. Aprotinin, corticosteroids and normosaline in the management of patellar tendinopathy in athletes: a prospective randomized study. *Sports Exercise and Injury* 1997;**3**:111–15.
66. **Lind B**, Öhberg L, Alfredson H. Sclerosing polidocanol injections in mid-portion Achilles tendinosis: remaining good clinical results and decreased tendon thickness at 2-year follow-up. 2006;**14**:1327–32.
67. **Hoksrud A**, Öhberg L, Alfredson H, *et al*. Ultrasound-guided sclerosis of neovessels in painful chronic patellar tendinopathy: a randomized controlled trial. *Am J Sports Med* 2006;**34**:1738–46.
68. **Alfredson HK**, Öhberg L. Increased intratendinous vascularity in the early period after sclerosing injection treatment in Achilles tendinosis: a healing response? *Knee Surg Sports Traumatol Arthrosc* 2006;**14**:399–401.
69. **Paoloni J**, Appleyard R, Nelson J, *et al*. Topical glyceryl trinitrate treatment of chronic noninsertional Achilles tendinopathy. *J Bone Joint Surg Am* 2004;**86-A**:916–21.
70. **Paoloni JA**, Appleyard RC, Nelson J, *et al*. Topical nitric oxide application in the treatment of chronic extensor tendinosis at the elbow. *Am J Sports Med* 2003;**31**:915–20.
71. **Paoloni JA**, Appleyard RC, Nelson J, *et al*. Topical glyceryl trinitrate application in the treatment of chronic supraspinatus tendinopathy: a randomized, double-blinded, placebo-controlled clinical trial. *Am J Sports Med* 2005;**33**:806–13.
72. **Kane TP**, Ismail M, Calder JD. Topical glyceryl trinitrate and noninsertional Achilles tendinopathy: a clinical and cellular investigation. *Am J Sports Med* 2008;**36**:1160–3.
73. **Langberg H**, Ellingsgaard H, Madsen T, *et al*. Eccentric rehabilitation exercise increases peritendinous type I collagen synthesis in humans with Achilles tendinosis. *Scand J Med Sci Sports* 2007;**17**:61–6.
74. **Shalabi A**, Kristoffersen-Wilberg M, Svensson L, *et al*. Eccentric training of the gastrocnemius-soleus complex in chronic Achilles tendinopathy results in decreased tendon volume and intratendinous signal as evaluated by MRI. *Am J Sports Med* 2004;**32**:1286–96.
75. **Öhberg L**, Alfredson H. Effects on neovascularisation behind the good results with eccentric training in chronic mid-portion Achilles tendinosis? *Knee Surg Sports Traumatol Arthrosc* 2004;**12**:465–70.
76. **Roos EM**, Engstrom M, Lagerquist A, *et al*. Clinical improvement after 6 weeks of eccentric exercise in patients with mid-portion Achilles tendinopathy -- a randomized trial with 1-year follow-up. *Scand J Med Sci Sports* 2004;**14**:286–95.
77. **Woodley BL**, Newsham-West RJ, Baxter GD, *et al*. Chronic tendinopathy: effectiveness of eccentric exercise. *Br J Sports Med* 2007;**41**:188–98.
78. **Visnes H**, Hoksrud A, Cook J, *et al*. No effect of eccentric training on jumper's knee in volleyball players during the competitive season: a randomized clinical trial. *Clin J Sport Med* 2005;**15**:227–34.
79. **Alfredson H**, Pietila T, Jonsson P, *et al*. Heavy-load eccentric calf muscle training for the treatment of chronic achilles tendinosis. *Am J Sports Med* 1998;**26**:360–6.
80. **Silbernagel KG**, Thomee R, Eriksson BI, *et al*. Continued sports activity, using a pain-monitoring model, during rehabilitation in patients with Achilles tendinopathy: a randomized controlled study. *Am J Sports Med* 2007;**35**:897–906.
81. **Khan KM**, Bonar SF, Cook JL, *et al*. Histopathology of common overuse tendon conditions: update and implications for clinical management. *Sports Med* 1999;**6**:393–408.
82. **September AV**, Posthumus M, van der Merwe L, *et al*. The COL12A1 and COL14A1 genes and Achilles tendon injuries. *Int J Sports Med* 2008;**29**:257–63.
83. **Arnoczky SP**, Lavagnino M, Egerbacher M. The mechanobiological aetiopathogenesis of tendinopathy: is it the over-stimulation or the under-stimulation of tendon cells? *Int J Exp Pathol* 2008;**88**:217–26.